



Research Article

## A Comparative Study of the Effects of Hybrid and Hyaluronic Acid Fillers on Secondary Intention Wound Healing

Mohammed Nadhem Mustafa<sup>\*1</sup>, Abdulhameed N. Aldabagh<sup>1</sup>

Abdulsattar S Mahmood<sup>2</sup>

<sup>1</sup> Oral and Maxillofacial Surgery Department/College of Dentistry/University of Mosul, Iraq

<sup>2</sup> Oral Diagnosis Department/College of Dentistry/University of Mosul, Iraq

\* Corresponding author: [mohammed.21dep61@student.uomosul.edu.iq](mailto:mohammed.21dep61@student.uomosul.edu.iq)

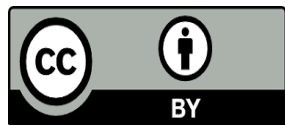
### Article History

Received: 3 September 2023

Revised: 11 October 2023

Accepted: 23 October 2023

Published online: 1 September 2025



**Copyright:** © 2025 by the authors. This article is an open-access article distributed under the terms and conditions of the Creative Commons Attribution (CC BY 4.0) license (<https://creativecommons.org/licenses/by/4.0/>).

**How to cite:** Mustafa MN., Aldabagh AN., Mahmood AS. A Comparative Study of the Effects of Hybrid and Hyaluronic Acid Fillers on Secondary Intention Wound Healing Al-Rafidain Dent J. 2025;25(2):271-286.

**ABSTRACT:** The current study aimed to compare the effects of a Hybrid filler (hyaluronic acid + calcium hydroxylapatite) and a hyaluronic acid filler (HA) on skin healing after induced wounds, using histological analysis. **Materials and Methods:** Three groups of three male Albino rats were randomly placed at the 3rd, 7th, and 14th repair times. Rats have three circular cuts on their backs. The top wound got hybrid filler (NEAUVIA STIMULATE®), the bottom right wound got hyaluronic acid filler (TEOSYAL RHA® 3), and the bottom left wound wasn't filled as a test. On days 3, 7, and 14, biopsies were taken from each rat and sent to a pathologist for histopathology. **Results:** The treated groups showed less inflammation than the control group, especially on the third and seventh days. On the fourteenth day, the tested groups had much lower granulation tissue production rates than the control group, which stayed high. On day 14, the hybrid filler group had the most re-epithelialization. **Conclusion:** The skin of rats healed faster with hybrid and HA fillers. They may help wounds heal.

**Keywords:** Hybrid Filler; HA Filler; Secondary Wound Healing.



[10.33899/rdenj.2023.143099.1222](https://doi.org/10.33899/rdenj.2023.143099.1222)

## INTRODUCTION

Cellular and molecular activity coordinates wound healing. Injury induces inflammation, tissue growth, and remodeling. Platelets and injured blood vessels release growth factors, cytokines, and other healing agents. Once a blood clot develops, inflammatory cells defend the site from infection. Keratinocyte migration and proliferation at the wound edge initiate cutaneous fibroblast multiplication. Fibroblasts produce several extracellular matrices. Granulation tissue develops during wound healing. Collagen formation and degradation in mature scar tissue. Mechanically weak scar tissue lacks epidermal appendages<sup>[1]</sup>.

Non-branched hyaluronic acid (HA) is a high-molecular-weight biopolysaccharide. This naturally occurring linear dipolysaccharide is composed of  $\beta$ -(1,3)-linked N-acetyl-D-glucosamine and  $\beta$ -(1,4)-linked D-glucuronic acid. The physicochemical and biological properties of this polyanionic polymer are unique. Because it is biological, endogenous, and natural, HA was selected as a polymer. HA is utilized in ocular surgery, arthritis therapy, wound healing, polymeric scaffolds, tissue engineering, cartilage regeneration, drug delivery, and, more recently, medicine delivery<sup>[2]</sup>.

The HA was utilized in animal studies. It promotes re-epithelialization, which results in elastic tissue and increased microvascular density in full-thickness surgical wound models<sup>[3]</sup>. During wound healing, hyaluronic acid promotes tissue regeneration, an inflammatory response, and angiogenesis<sup>[4]</sup>.

Dermal fillers have the potential to decrease facial lines and wrinkles. Because the body absorbs most wrinkle fillers, they are only temporary. The most common injectable fillers are hyaluronic acid fillers because they are safe, effective, reversible, and provide long-lasting, natural-looking results with minimal recovery time. These fillers are created by crosslinking HA chains with 1,4-butanediol diglycidyl ether<sup>[5]</sup>.

Microspheres of calcium hydroxylapatite are dispersed across an aqueous carrier gel to form the biodegradable filler. Injecting a soluble carrier gel allows for even distribution and spacing of microspheres. Microspheres boost regional collagen production after gel absorption<sup>[6]</sup>.

For unexpected results, hybrid filler reinforcement combines two or more fillers in a composite. The term "hybrid" refers to a varied entity. The fillers in this category vary chemically and physically. Many doctors combine the use of HA and CaHA fillers to take advantage of their synergistic advantages<sup>[7]</sup>.

## MATERIALS AND METHODS

The protocol of this study was conducted in vivo, submitted, and approved by the Local Ethics Committee (Uom.Dent. 22/23) Research Ethics Committee of the College of Dentistry, University of Mosul, Mosul, Iraq.

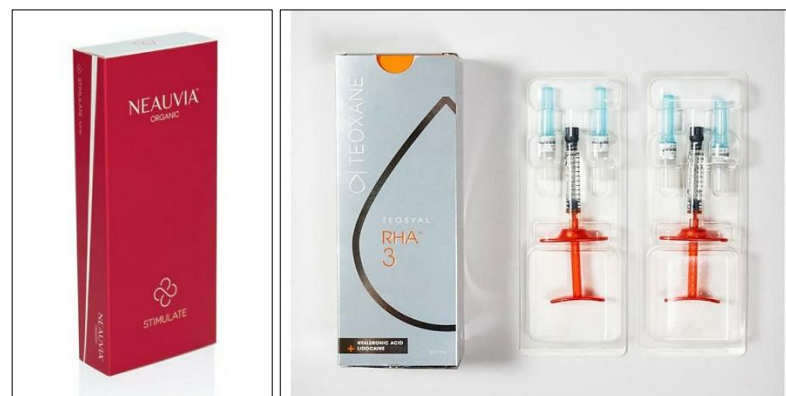### Experimental Model

The study employed nine (250-350-gram) male albino rats, aged 4-6 months<sup>[8]</sup>. The animals were fed water and commercial feed (grain, fruit, and vegetables) and lived at the animal house in special cages at temperatures of 18-22 °C. All tests on animals followed the process for animal care to avoid health problems and make the tests more effective.

Three rodents were randomly allocated to each of the three healing periods (3rd, 7th, and 14th days<sup>[9]</sup>. Veterinarians checked the animal's health and nutrition. State inspections looked for infectious and general illnesses.

### Materials

TEOSYAL RHA® 3, hyaluronic acid dermal filler (23mg/ml), Switzerland. NEAUVIA STIMULATE® (26mg/ml hyaluronic acid +1% calcium hydroxyapatite) filler, Switzerland Figure (1).



**Figure (1):** NEAUVIA STIMULATE filler, TEOSYAL RHA3 filler.

### Surgical Procedure

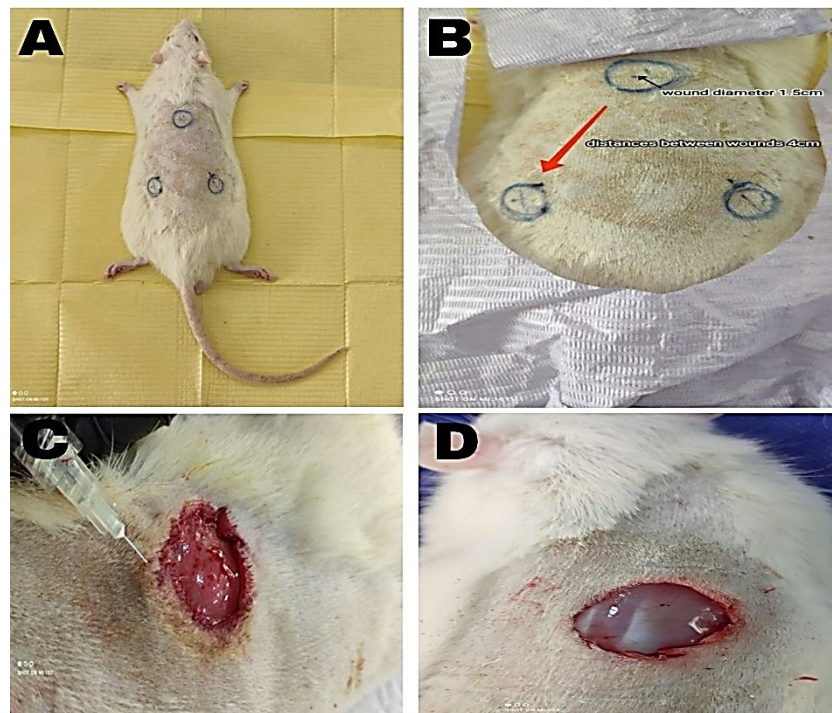
#### Anesthetic Method

Intraperitoneal injections of ketamine® 50mg/kg and xylazine® 5mg/kg sedated the animal<sup>[10]</sup>.

#### Surgical Method

1. The rats were sedated and shaved using scissors and an electric hair clipper. Following that, the surgical site was disinfected with 10% povidone-iodine.

2. Each rat's dorsum was marked with three circular parts. The wounds were 1.5 cm broad and 4 cm apart. One wound (upper wound) was selected for injection with hybrid filler (NEAUVIA STIMULATE®), another (lower right) with HA filler (TEOSYAL RHA® 3), and the control site (lower left) was left uninjected (Figure 1).
3. Wound formation: Blade no.15 was used to produce 1.5cm circular incisions on the specified skin while leaving the underlying muscle layer intact, Figure (1).
4. The top wound was promptly injected with 0.1ml<sup>[11]</sup> of NEAUVIA STIMULATE dermal filler (HA+ CaHA) at the circle's perimeter (intra-dermal) at equal distances. The lower right wound was filled with 0.1ml TEOSYAL RHA® 3 hyaluronic acid dermal filler. The control wounds were not injected (Figure 2).
5. To minimize infection, the surgical site was covered and compressed with a compression bandage after skin removal. The animals were kept in separate cages to minimize wound infection.



**Figure (2):** Surgical procedure. **A, B:** shaving the area and marking the circles, **C, D:** wound creation and filler injection.

### Biopsy Collection

Excisional biopsies were performed on three rats from each group on the third, seventh, and fourteenth days of the study. The rat wounds were biopsied.

**Group day three:** After 3 days from the surgery, the rats were euthanized at the animal house.

**Group one week:** After 7 days from the surgery, the rats were euthanized.

**Group two weeks:** The rats were euthanized after 14 days from surgery.

Skin samples were maintained in sterile containers with 10% formalin solution and sent for histopathology at predetermined intervals.

### **Histological Criteria**

#### **A. Inflammatory Cells Infiltration Criteria** <sup>[12]</sup>

Score 1: Nil, in the absence of observable inflammatory cells within the surgical field.

Score 2: A small quantity of mild inflammatory cells was observed, comprising less than half of the field.

Score 3: When inflammatory cells are observed in over 50% of the field, a moderate level of inflammation is present.

Score 4: When a significant quantity of inflammatory cells is present in more than 75% of the field, the condition can be described as either severe or abundant.

#### **B. Granulation Tissue Formation Criteria** <sup>[13]</sup>

Score 1: The wound exhibits a lack of granulation tissue formation.

Score 2: The amount of granulation tissue formed in the wound gap is limited.

Score 3: The formation of granulation tissue is observed to be at a moderate level.

Score 4: The extent of granulation tissue formation in the wound is significant.

#### **C. Re-epithelialization Criteria** <sup>[14]</sup>

Score 0: The process of re-epithelialization occurring at the periphery of the wound is observed.

Score 1: The re-epithelialization process has resulted in coverage of less than 50% of the wound.

Score 2: The process of re-epithelialization has resulted in the coverage of over 50% of the wound.

Score 3: The wound has undergone re-epithelialization, with coverage extending over its entirety. However, the thickness of the covering is irregular.

Score 4: The wound has undergone re-epithelialization, resulting in complete coverage with normal thickness.

## **RESULTS**

All slides were blindly examined by three qualified histopathologists who received only the codes for each group to prevent any bias. Histometric analysis was done depending on scores that are inflammatory cells infiltration (ICI), granulation tissue formation (GTF), and re-epithelialization (RE).

In our study's histological sections, group (A) refers to hybrid filler (HA+CaHA), group (B) to hyaluronic acid (HA) filler, and group (C) to the control group.

### **1. Skin Histology Findings of the Third Day**

#### **A. Inflammatory Cells Infiltration**

In the hybrid filler and HA filler group, less than half of the wounds' fields demonstrated mild predominance of acute inflammatory poly morphonuclear leukocytes (neutrophils). In the control incision group, the scores showed an abundant number of inflammatory cells infiltration, figures (3,4).

#### B. Granulation Tissue Formation

All groups showed moderate amount of granulation tissue formation with angiogenesis on this day, figures (3,4).

#### C. Re-epithelialization

Less than half of the wound was re-epithelialized in the hybrid filler and HA filler groups. In the control group, the wound edges had already begun to re-epithelialize, figures (3,4).

### 2. Skin Histology Findings of the Seventh Day

#### A. Inflammatory Cells Infiltration

In comparison to the control group, which had a considerable quantity of inflammatory cell infiltration, both the hybrid filler and HA filler groups had minimal numbers of inflammatory cells, less than half of the wound, figures (5,6).

#### B. Granulation Tissue Formation

In both the hybrid filler and HA filler groups, granulation tissue with angiogenesis was seen in a moderate amount. The angiogenesis and granulation tissue development in the control group were more developed (Figures 5,6).

#### C. Re-epithelialization

The wounds treated with hybrid filler and HA filler both resulted in re-epithelialization of more than 50% of the region. Less than half of the wound surface area was re-epithelialized in the control group, figures (5,6).

### 3. Skin Histology Findings of Fourteenth Day

#### A. Inflammatory Cells Infiltration

The hybrid filler and HA filler slides revealed no inflammatory cells infiltration. The control group demonstrated scant inflammatory cell infiltration, figures (7,8).

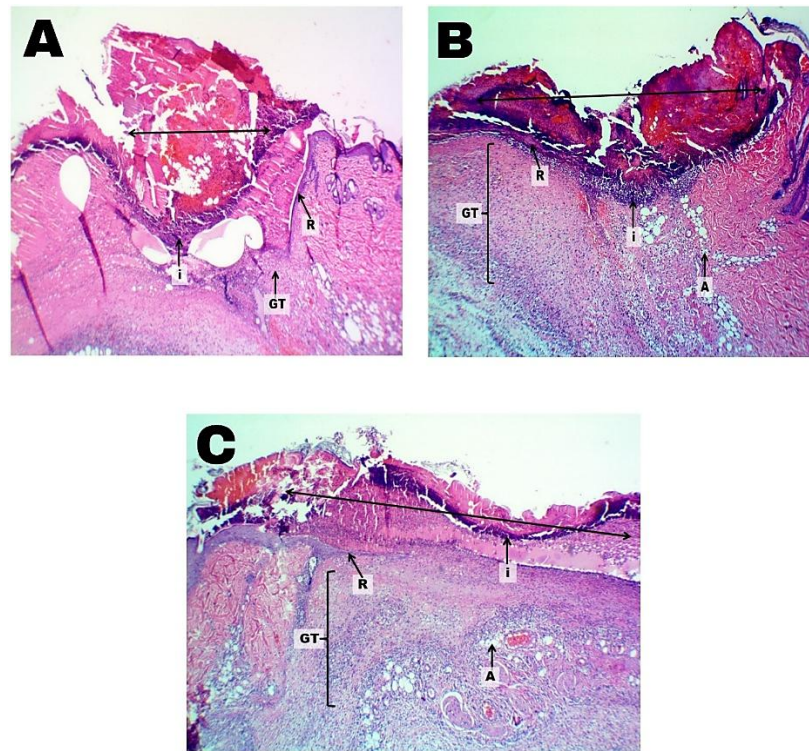
#### B. Granulation Tissue Formation

After two weeks, the wounds in the hybrid filler and HA filler groups showed a small amount of granulation tissue production with angiogenesis. The granulation tissue of the control group was well advanced, figures (7,8).

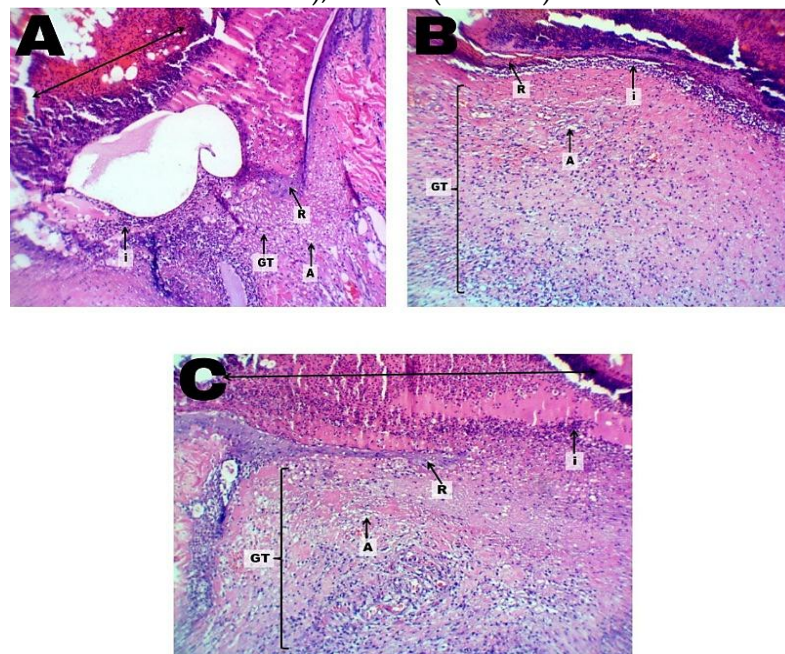
#### C. Re-epithelialization

The wound in the hybrid filler group was re-epithelialized with an even thickness. The re-epithelialization of wounds in HA samples was well developed but not uniform in thickness. More over half of the wounds in the control group had re-epithelialized, figures (7,8).

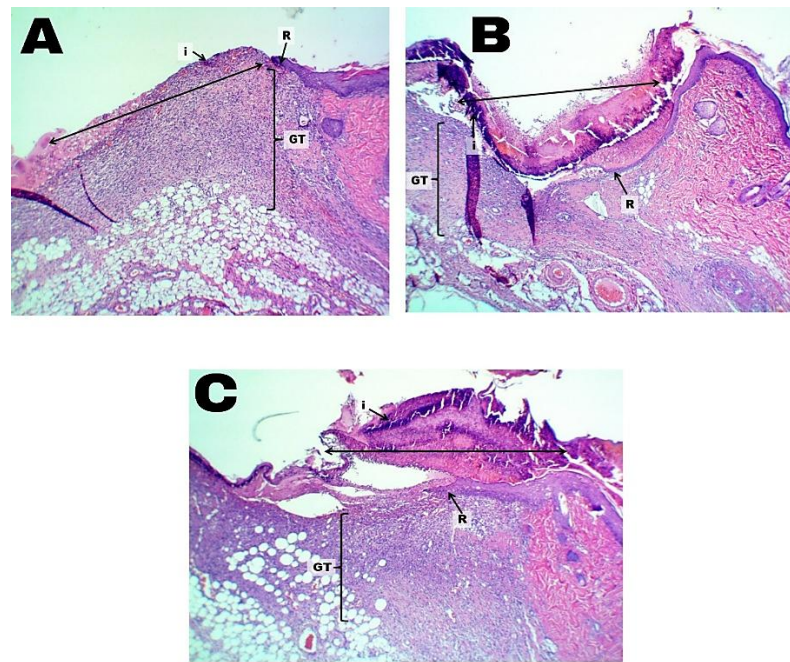




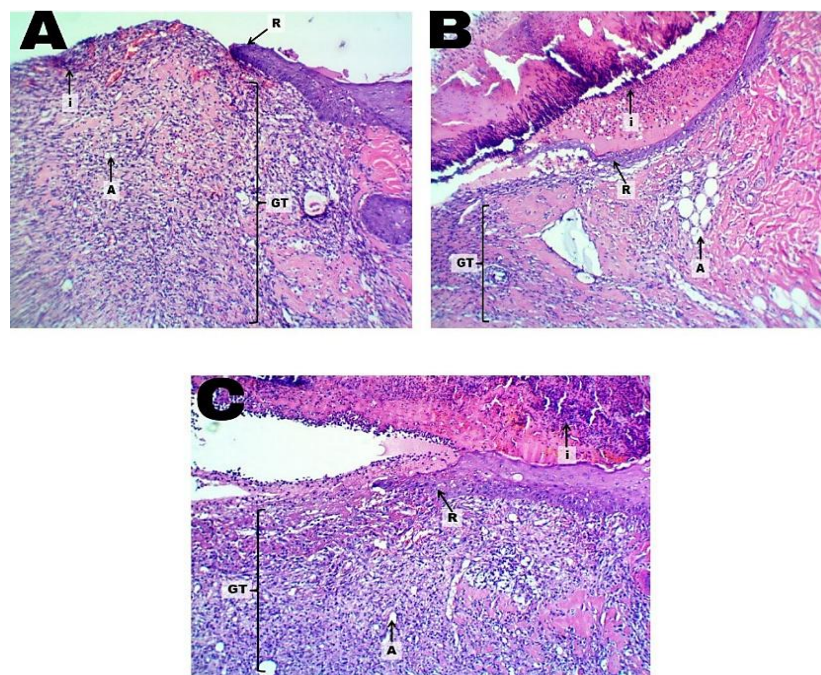
**Figure (3):** Histological section of rat skin (after 3 days) showing wound site (↔), containing inflammatory cells infiltration (i), re-epithelialization (R), granulation tissue (GT), angiogenesis (A). H&E stain, 40X. A (hybrid filler), B (hyaluronic acid filler), and C (control).



**Figure (4):** Another histological section of rat skin (after 3 days) showing wound site (↔), containing inflammatory cells infiltration (i), re-epithelialization (R), granulation tissue (GT), angiogenesis (A). H&E stain, 100X. A (hybrid filler), B (hyaluronic acid filler), and C (control).

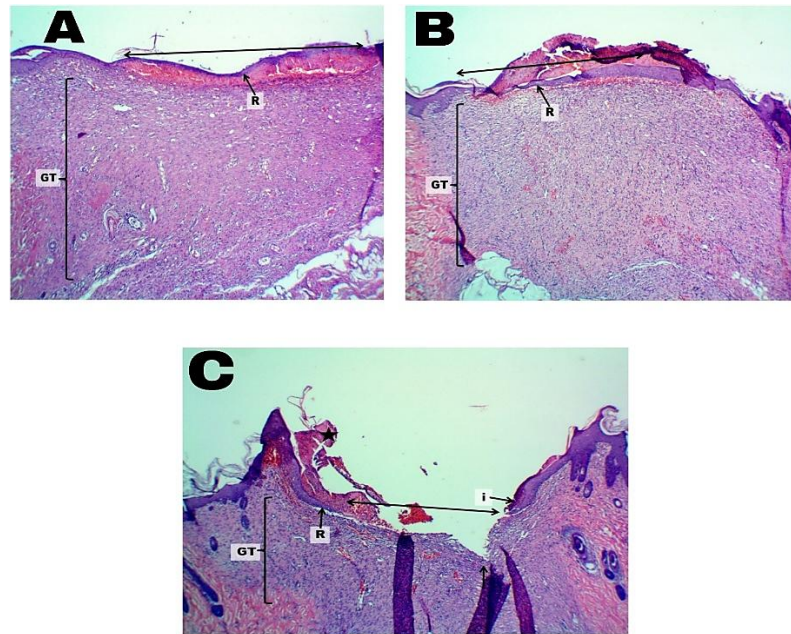


**Figure (5):** Histological section of rat skin (after 7 days) showing wound site ( $\leftrightarrow$ ), containing inflammatory cells infiltration (i), re-epithelialization (R), granulation tissue (GT). H&E stain, 40X. A (hybrid filler), B (hyaluronic acid filler), and C (control).

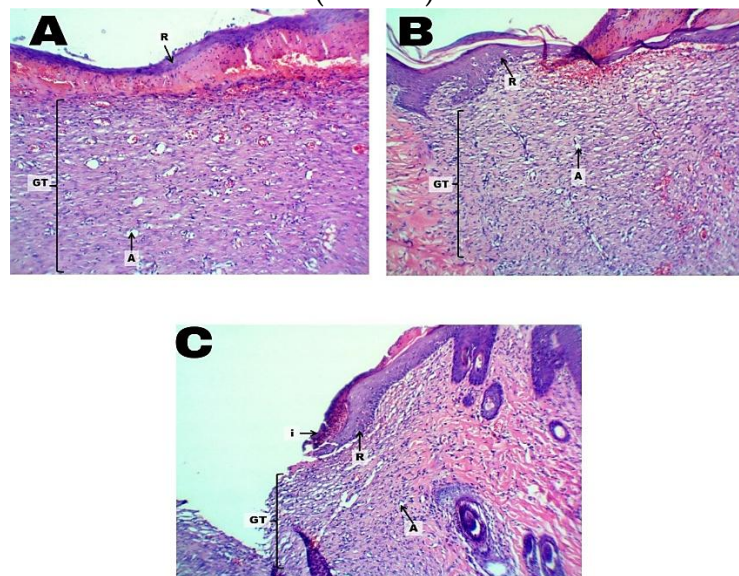


**Figure (6):** Another histological section of rat skin (after 7 days) showing wound site ( $\leftrightarrow$ ), containing inflammatory cells infiltration (i), re-epithelialization (R), granulation tissue (GT). H&E stain, 100X. A (hybrid filler), B (hyaluronic acid filler), and C (control).





**Figure (7):** Histological section of rat skin (after 14 days) showing wound site (↔), containing inflammatory cells infiltration (i), re-epithelialization (R), granulation tissue (GT). H&E stain, 40X. A (hybrid filler), B (hyaluronic acid filler), and C (control).



**Figure (8):** Another histological section of rat skin (after 14 days) showing wound site (↔), containing inflammatory cells infiltration (i), re-epithelialization (R), granulation tissue (GT). H&E stain, 100X. A (hybrid filler), B (hyaluronic acid filler), and C (control).

**Table (1):** The histopathological Scores of the inflammatory cells infiltration (ICI), granulation tissue formation (GTF), and re-epithelialization (RE) of the treatment groups (A: hybrid filler, B: hyaluronic acid filler) and the control group (C) as Median at 3<sup>rd</sup> (G1), 7<sup>th</sup> (G2) and 14<sup>th</sup> (G3) days of the study period.

Time	Group	Median of ICI	Median of GTF	Median of RE
3 <sup>rd</sup> Day	G1A	2	3	1
	G1B	2	3	1
	G1C	4	3	0
7 <sup>th</sup> Day	G2A	2	3	2
	G2B	2	3	2
	G2C	3	4	1
14 <sup>th</sup> Day	G3A	1	2	4
	G3B	1	2	3
	G3C	2	4	2

**Table (2):** Statistical comparisons of the histopathological scores as inflammatory cells infiltration (ICI), granulation tissue formation (GTF), and re-epithelialization (RE) between the control group and the treatment A (hybrid filler) group at the same day.

Time period	ICI (P-value)	GTF (P-value)	RE (P-value)
3 <sup>rd</sup> Day	0.024*	0.700	0.034*
7 <sup>th</sup> Day	0.043*	0.043*	0.034*
14 <sup>th</sup> Day	0.034*	0.025*	0.025*

Mann-Whitney U test was used for the comparisons between groups at  $p \leq 0.05$ . (\*): Significant difference.

**Table (3):** Statistical comparisons of the histopathological scores as inflammatory cells infiltration (ICI), granulation tissue formation (GTF), and re-epithelialization (RE) between the control group and the treatment B (hyaluronic acid filler) group at the same day.

Time period	ICI (P-value)	GTF (P-value)	RE (P-value)
3 <sup>rd</sup> Day	0.025*	0.796	0.034*
7 <sup>th</sup> Day	0.043*	0.043*	0.043*
14 <sup>th</sup> Day	0.034*	0.025*	0.034*

The Mann-Whitney U test was used for the comparisons between groups at  $p \leq 0.05$ . (\*): Significant difference.

**Table (4):** Statistical comparisons of the histopathological scores as inflammatory cells infiltration (ICI), granulation tissue formation (GTF), and re-epithelialization (RE) between both treatment A (hybrid filler) and B (HA filler) groups on the same day.

Time period	ICI (P-value)	GTF (P-value)	RE (P-value)
3 <sup>rd</sup> Day	0.317	0.197	1.000
7 <sup>th</sup> Day	0.700	1.000	1.000
14 <sup>th</sup> Day	1.000	1.000	0.034*

The Mann-Whitney U test was used for the comparisons between groups at  $p \leq 0.05$ . (\*): Significant difference.

## DISCUSSION

Excisional wounds, which are the most common wound healing model, need second intention healing without sutures, much like acute clinical wounds. Haemorrhage, inflammation, granulation tissue, re-epithelialization, angiogenesis, and remodelling may all be examined in this model<sup>[15]</sup>.

During the initial phase of wound healing, inflammation is considered a critical period essential for clearing contaminating bacteria and creating a favorable environment for regenerating and repairing tissue events. Dysregulations of the immune response during wound healing, such as excessive levels of pro-inflammatory cytokines, lead to aberrations in immune cell recruitment, changes in proteolytic balance, and impaired blood vessel formation. The latter causes the wound to stagnate in the inflammatory reaction phase, resulting in delayed healing or chronic wounds<sup>[16]</sup>. The inflammatory phase was recorded during the first 3 days of healing, then declined after 7 days, and was completely removed at 14 days<sup>[17]</sup>.

On the third day, the hybrid filler and HA groups showed mild inflammation, while the control group showed severe inflammation. This indicates a significant difference in inflammation between treatment groups and controls. According to Trombelli et al. 2018, hyaluronic acid is bacteriostatic and anti-inflammatory<sup>[18]</sup>. Urdiales-Gálvez et al. 2023 found that hybrid fillers (hyaluronic acid with calcium hydroxylapatite) for skin rejuvenation caused moderate irritation that disappeared within 48 hours without therapy<sup>[19]</sup>. On day 3, the experimental and control groups demonstrated moderate granulation tissue development. In comparison to the control group, which exhibited re-epithelialization only along the wound margin, re-epithelialization was more rapid in the treatment groups that covered less than half of the wound. In his study, Kawano et al. 2021 found that HA increases epidermal cell migration within 6 hours, which reduces wound area<sup>[20]</sup>. Kim 2019 showed that

intra dermal micro-droplet injections of CaHA filler caused fibroblast neocollagenesis and micro-blood circulation (neovascularization), which helped re-epithelialization<sup>[21]</sup>.

On the seventh day, hyaluronic acid's anti-inflammatory capabilities were shown when both treatment groups showed little inflammation and were still lower than the control group. This agrees with Marinho et al. 2021<sup>[22]</sup>. Calcium hydroxyapatite medicines with hyaluronic acid injected into rats' soft tissues had reduced inflammation<sup>[23]</sup>. Median scores indicated that treatment groups had less granulation tissue than the control group. When compared to the control group, which had less than half of the incision re-epithelialized after 7 days, both treatment groups performed better. This showed that the wounds of the study groups healed more quickly. Gao et al. 2019 showed that HA promotes re-epithelialization and angiogenesis in rats' wounds<sup>[24]</sup>.

Unlike the control group, the hybrid filler and HA filler groups experienced complete remission of the inflammatory process on the fourteenth day. Urdiales-Galvez et al. 2023 discovered no irritation after the use of the hybrid filler<sup>[19]</sup>. Neither treatment group showed significant granulation tissue development on this day. The control group, on the other hand, had an abundance of granulation tissue. On day 14, macrophages synthesize TNF- $\alpha$  from HA. TNF- $\alpha$  inhibits granulation tissue, fibroblastic collagen synthesis, and scarring<sup>[25]</sup>. The hybrid filler that completely covered the wound with a normal thickness received the highest median ratings for re-epithelialization. The median score for HA fillers was lower than for hybrid fillers with irregular thickness. The control group had the lowest wound re-epithelialization rate (greater than 50%).

## CONCLUSIONS

Within the limitations of the current study, it is possible to conclude that:

Both medications considerably improved secondary intention wounds and had a beneficial influence on healing acceleration in terms of epithelial healing following injection, according to our findings. We may suggest that you consider utilizing a hybrid filler or hyaluronic acid filler as an alternate way to treat wounds.

**Acknowledgment:** Thanks to the Department of Oral and Maxillofacial Surgery at Mosul University for their assistance in this research. Thank you to everyone in the College of Dentistry who assisted and supported me in any manner throughout this project.



**Authors' Contribution**

Mustafa MN contributed to conceptualization, validation, and writing the original draft. Aldabagh AN was responsible for formal analysis, methodology, project administration, supervision, and review & editing of the manuscript. Mahmood AS contributed to the investigation, software, validation, and visualization. Aldabagh AN and Mahmood AS were involved in data curation, resources, and review & editing. All authors have read and approved the final manuscript.

**Funding:** This study is self-funded

**Ethical statement:** The protocol of this study was approved by the Local Ethics Committee (Uom. Dent. 22/23), Research Ethics Committee of the College of Dentistry, University of Mosul, Mosul, Iraq.

**Conflict of interest**

The authors declare that there are no conflicts of interest regarding the publication of this manuscript.

**Availability of data and materials:** Data is available at the request of the corresponding author.

**Declaration of Generative AI and AI-assisted technologies**

During the preparation of this work, the authors used an AI service to improve the manuscript's readability and correct grammatical issues. The authors reviewed and edited the content as needed and take full responsibility for the content of the publication.

**REFERENCES**

1. Mendonça RJd, Coutinho-Netto J. Cellular aspects of wound healing. *Anais brasileiros de dermatologia*. 2009;84:257-262.
2. Baviskar K, Shaikh T, Patil K, Baviskar R, Lodhi S. Role of hyaluronic acid based hydrogel in management of wound healing effect. *Advance Pharmaceutical Journal*. 01/01 2019;4:152-160.

3. Celani LMS, Lopes IS, Medeiros AC. The effect of hyaluronic acid on the skin healing in rats. *JOURNAL OF SURGICAL AND CLINICAL RESEARCH*. 2019;10(2):65-75.
4. Shaharudin A, Aziz Z. Effectiveness of hyaluronic acid and its derivatives on chronic wounds: a systematic review. *Journal of wound care*. 2016;25(10):585-592.
5. Pierre S, Liew S, Bernardin A. Basics of dermal filler rheology. *Dermatologic surgery*. 2015;41:S120-S126.
6. Chang JW, Koo WY, Kim E-K, Lee SW, Lee JH. Facial rejuvenation using a mixture of calcium hydroxylapatite filler and hyaluronic acid filler. *Journal of Craniofacial Surgery*. 2020;31(1):e18-e21.
7. Moradi A, Shirazi A, David R. Nonsurgical chin and jawline augmentation using calcium hydroxylapatite and hyaluronic acid fillers. *Facial Plastic Surgery*. 2019;35(02):140-148.
8. Koksall V, Mercantepe T, Tumkaya L, Oktem IS. Less Use of the Bipolar Cautery can Prevent Postlaminectomy Epidural Fibrosis: An Experimental Study in Rats. *Turkish Neurosurgery*. 2019;30(2).
9. Camacho-Alonso F, López-Jornet P. Clinical-pathological study of the healing of wounds provoked on the dorso-lingual mucosa in 186 albino rats. *Otolaryngology—Head and Neck Surgery*. 2007;136(1):119-124.
10. Parikh KS. *Nano-structured, drug-eluting medical devices for improved clinical outcomes*, Johns Hopkins University; 2017.
11. Huh J-B, Kim J-H, Kim S, et al. Effects of PMMA and cross-linked dextran filler for soft tissue augmentation in rats. *International Journal of Molecular Sciences*. 2015;16(12):28523-28533.
12. Sultana J, Molla MR, Kamal M, Shahidullah M, Begum F, Bashar MA. Histological differences in wound healing in maxillofacial region in patients with or without risk factors. *Bangladesh Journal of Pathology*. 2009;24(1):3-8.
13. Gupta A, Kumar P. Assessment of the histological state of the healing wound. *Plastic and Aesthetic Research*. 2015;2:239-242.
14. Sinha UK, Gallagher LA. Effects of steel scalpel, ultrasonic scalpel, CO2 laser, and monopolar and bipolar electrosurgery on wound healing in guinea pig oral mucosa. *The Laryngoscope*. 2003;113(2):228-236.
15. Masson-Meyers DS, Andrade TA, Caetano GF, et al. Experimental models and methods for cutaneous wound healing assessment. *International journal of experimental pathology*. 2020;101(1-2):21-37.
16. Schilrreff P, Alexiev U. Chronic inflammation in non-healing skin wounds and promising natural bioactive compounds treatment. *International journal of molecular sciences*. 2022;23(9):4928.

17. Khalaf AA, Hassanen EI, Zaki AR, Tohamy AF, Ibrahim MA. Histopathological, immunohistochemical, and molecular studies for determination of wound age and vitality in rats. *International Wound Journal*. 2019;16(6):1416-1425.
18. Trombelli L, Simonelli A, Pramstraller M, et al. Clinical efficacy of a chlorhexidine-based mouthrinse containing hyaluronic acid and an antidiscoloration system in patients undergoing flap surgery: a triple-blind, parallel-arm, randomized controlled trial. *International Journal of Dental Hygiene*. 2018;16(4):541-552.
19. Urdiales-Gálvez F, Braz A, Cavallini M. Facial rejuvenation with the new hybrid filler HArmonyCa™: Clinical and aesthetic outcomes assessed by 2D and 3D photographs, ultrasound, and elastography. *Journal of Cosmetic Dermatology*. 2023.
20. Kawano Y, Patrúlea V, Sublet E, et al. Wound healing promotion by hyaluronic acid: Effect of molecular weight on gene expression and in vivo wound closure. *Pharmaceuticals*. 2021;14(4):301.
21. Kim J. Multilayered injection of calcium hydroxylapatite filler on ischial soft tissue to rejuvenate the previous phase of chronic sitting pressure sore. *Clinical, Cosmetic and Investigational Dermatology*. 2019:771-784.
22. Marinho A, Nunes C, Reis S. Hyaluronic acid: a key ingredient in the therapy of inflammation. *Biomolecules*. 2021;11(10):1518.
23. Larkina S, Seletska O, Makarenko O, Vastyanov R, Badiuk N. Study of osteoplastic and anti-inflammatory efficiency of drugs containing calcium hydroxyapatite and hyaluronic acid. 2021.
24. Gao Y, Sun Y, Yang H, et al. A low molecular weight hyaluronic acid derivative accelerates excisional wound healing by modulating pro-inflammation, promoting epithelialization and neovascularization, and remodeling collagen. *International journal of molecular sciences*. 2019;20(15):3722.
25. Hameed MA, Abbas MK, Madlum KN. Role of hyaluronic acid in modulating wound healing progression. *Systematic Reviews in Pharmacy*. 2020;11(11):1844-1850.

### دراسة مقارنة لتأثيرات الحشو الهجين وحامض الهيالورونيك على التئام الجروح الثانوية

محمد ناظم مصطفى,<sup>1</sup> عبد الحميد ناطق الدباغ,<sup>1</sup> عبد الستار سالم محمود<sup>2</sup>

<sup>1</sup> قسم جراحة الفم والوجه والفكين / كلية طب الأسنان / جامعة الموصل ، العراق

<sup>2</sup> قسم تشخيص الفم / كلية طب الأسنان / جامعة الموصل ، العراق

**الملخص**

**الأهداف:** لمقارنة تأثيرات الفلر الهجين (حمض الهيالورونيك + هيدروكسيلايت الكالسيوم) وفلر حمض الهيالورونيك على التئام الجلد بعد الجروح المستحثة باستخدام التحليل النسيجي. **المواد وطرائق العمل:** تم وضع ثلاث مجموعات من ثلاثة ذكور جرذان ألبينو بشكل عشوائي في أوقات الإصلاح الثالث والسابع والرابع عشر. الفئران لديها ثلاث جروح دائرية على ظهورهم. حصل الجرح العلوي على الفلر الهجين، الجرح الأيمن السفلي حصل على فلر حمض الهيالورونيك، ولم يتم ملء الجرح الأيسر السفلي كاختبار. في الأيام الثالث والسابع والرابع عشر، تم أخذ الخزعات من كل فأر وإرسالها إلى أخصائي علم أمراض الأنسجة. **النتائج:** أظهرت المجموعات المعالجة التهاباً أقل من مجموعة السيطرة، خاصة في اليومين الثالث والسابع. في اليوم الرابع عشر، كان لدى المجموعات المعالجة معدلات إنتاج أنسجة حبيبية أقل بكثير من مجموعة السيطرة، والتي ظلت مرتفعة. في اليوم الرابع عشر، كانت مجموعة الفلر الهجين هي الأكثر في عملية إعادة تكوين النسيج الظهاري. **الاستنتاجات:** شفاء جلد الفئران بشكل أسرع باستخدام الفلر الهجين وفلر حمض الهيالورونيك. قد تساعد في التئام الجروح.

**الكلمات المفتاحية:** حشو هجين ، حشو هكتار ، التئام الجروح الثانوي.