

The Effects of Dried Amniotic Membrane on Epithelialization in Secondary Wound Healing : An Experimental Study

Zaid A. Muhammad
BDS (Assist Lect)

Department of Oral and Maxillofacial Surgery
College of Dentistry, University of Mosul

Dr. Attalla Fathi Rejab
BDS, M.Sc., FIMS (Lect)

Department of Oral and Maxillofacial Surgery
College of Dentistry, University of Mosul

الخلاصة

الاهداف: يهدف البحث إلى تقييم المقاطع النسيجية لمراحل الالتئام للجروح الثانوية في الأرانب باستخدام الغشاء السلوي كغشاء حيوي .
المواد وطرائق العمل: لغرض إجراء الدراسة تم التخطيط لاستخدام عشرين أرنباً محلياً من الذكور. وقد تم إجراء عييين جراحيين في منطقة الظهر ، كل منهما بقطر 10 ملم وبشكل دائري، العيب من جهة اليمين تم تغطيته بالغشاء السلوي ثم غطي بالضماد التقليدي . والعيب من جهة اليسار غُطي بالضماد التقليدي فقط. وقد قسمت الأرانب إلى أربع مجاميع على حسب أيام التضحية (3، 7، 14، 30) يوماً. بعد ذلك جمعت العينات بعد التضحية فوراً . بعد ذلك وضعت العينات في الفورمالين وأرسلت لغرض الدراسة النسيجية المختبرية. **النتائج:** أظهرت نتائج التقييم النسيجي فرقاً معنوياً في مجموعة ال (14) يوماً لقياس الالتئام عند ($p\text{-value} < 0.05$) لصالح مجموعة الغشاء السلوي، بينما لم يكن هناك فرق معنوي في مجموعة (7، 14، 30) يوماً. **الاستنتاجات:** يمكن الاستنتاج من هذه الدراسة، أن الغشاء السلوي يمكن أن يستخدم كغشاء حيوي، لتحفيز عملية الالتئام في الجروح الثانوية.

ABSTRACT

Aims: To investigate the efficacy of dried gamma-irradiated amniotic membrane dressing for the healing of full-thickness skin wounds, using a rabbit model. **Materials and Methods:** This study was performed in the Oral and Maxillofacial surgery Department, College of Dentistry, University of Mosul, Iraq. Twenty, locally bred, six to eight months old male rabbits were planned to conduct the study. Bilateral full-thickness circular segments approximately 10 mm in diameter and nearly (3-4)mm in thickness were excised from the the back of each rabbit (near to the mid-dorsum area) with a surgical blade; one dorsal skin wounding was performed lateral to the midline on right side, the other wound was performed lateral to the midline on left side. The right wound was used as an experimental wound and covered with dried amniotic membrane whereas the left wound was considered as a control wound. All wounds were covered with non adherent moist occlusive gauze. Animals were divided into four groups according to sacrificing date (3, 7, 14, 30) days. Skin specimens were collected after sacrificing the rabbits. The specimens were placed in formaldehyde and sent for histopathological examination and scoring for wound healing. **Results:** The histopathological findings of this study revealed that there was a significant difference of reepithelialization between the two groups at two weeks period, at $p\text{-value} < 0.05$, while there was no significant difference at 3 days, one week, and one month. **Conclusions:** This study concluded that amniotic membrane can be used as a safe dressing, promoting epithelialization on secondary wounds.

Key Words: Amniotic membrane, Secondary wound, Epithelialization.

Muhammad ZA, Rejab AF. The Effects of Dried Amniotic Membrane on Epithelialization in Secondary Wound Healing : An Experimental Study. *Al-Rafidain Dent J.* 2016(1): 49-58.

Received: 15/7/2013

Sent to Referees: 25/8/2013

Accepted for Publication: 31/10/2013

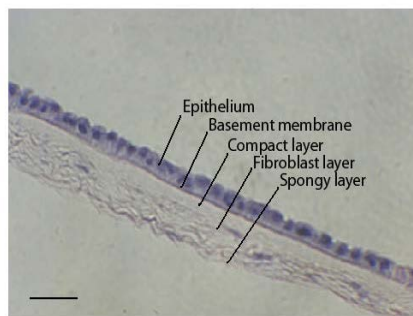
INTRODUCTION

Wound healing is the body's natural biological process for regenerating dermal and epidermal tissue. This process involves time and a balanced activity of inflammatory, vascular, connective tissue, and epithelial cells leading to the restoration of skin integrity ⁽¹⁾. Although many efforts have been made, wound healing has become an increasingly difficult clinical, scientific and economic problem, especially taking into account the current population development ⁽²⁾. In clinical practice, the best way to heal a wound is to close it according to surgical standards as quickly as possible after injury. However, this procedure is limited to those wounds located in anatomical regions that permit adaptation of wound borders allowing wound closure by primary intention. This means closing it by suturing and restoring of the skin continuity ⁽³⁾. In large-surface and deep wounds in which primary wound closure is neither possible nor practicable, the most important issue is to dress the wound with appropriate materials in order to keep it free from

infection, to reduce or eliminate pain and all potential factors inhibiting natural healing, and to replace or substitute the missing tissue as much as possible ⁽⁴⁾.

Current strategies point out the acceleration of the wound repair by systematically designed dressing materials. By this direction, most efforts have experimentally and clinically utilized the biologically derived, which are capable of accelerating the healing processes at molecular, cellular, and systemic levels, as materials to produce wound dressings ^(5,6,7).

Amniotic membrane is a tissue of interest as a biological dressing due to its biological properties and immunologic characteristics. It has low immunogenicity and beneficial re-epithelialization effects, with anti-inflammatory, antifibrotic, anti-microbial, and non-tumorigenic properties ⁽⁴⁾. The amniotic membrane is the innermost layer of the fetal membrane, which first appears at about days 7–8 following conception. It results from a separation from the inner cell mass of the germ disk at the periphery of the ectodermal layer ⁽⁸⁾. As shown in Figure (1)



Figure(1): Haematoxylin and eosin staining of the fresh amniotic membrane(9). Scale bar: 50 μ m

The amniotic membrane(AM) consists of five layers from within outward: epithelium, basement membrane, compact layer, fibroblast layer and spongy layer (9). The epithelium consists of a single layer of

epithelial cells which are polygonal in shape ⁽¹⁰⁾. The basement membrane of the AM which contains types I, III, IV, V collagen, laminin-1, laminin-5 and fibronectin, plays an important role in the other cells prolifera-

tion and differentiation^(9,11). The compact layer is a dense layer almost totally devoid of cells and consists mainly of a complex reticular network. The fibroblastic layer is the thickest layer of the amnion and consists of mesenchymal cells. The spongy layer forms the interface between the AM and chorion and consists of wavy bundles of reticulum bathed in mucin. This layer is normally separated from fibroblast layer when the AM is peeled from the underlying chorion. The AM varies in thickness from 0.02 mm to 0.5 mm, so it can easily be used as a biological dressing in ischemic areas⁽¹⁰⁾.

The AM has low immunogenicity, and well-documented re-epithelialization effects, anti-inflammatory, anti-fibrotic, anti-microbial, and non-tumorigenic properties. The AM has low immunogenicity, and well-documented re-epithelialization effects, anti-inflammatory, anti-fibrotic, anti-microbial, and non-tumorigenic properties. These pleiotropic functions are related in

part to its capacity to synthesize and release biological active substances including cytokines and signaling molecules such as the tumor necrosis factor, interferon, transforming growth factor (TGF)- α , TGF- β , basic fibroblastic growth factor, epidermal growth factor, keratinocyte growth factor, hepatic growth factor, interleukin-4 (IL-4), IL-6, IL-8, natural inhibitors of metalloproteinases, defensins, prostaglandins etc⁽¹²⁻¹⁴⁾.

In wounds healing by secondary intention reepithelialization occurs after the wound defect is filled with granulation tissue. As the cells migrate, they increase in number by mitosis. Once the wound is covered with cells, cellular differentiation occurs, restoring normal epithelial layers. Epithelialization proceeds at approximately 1 mm/day^(23,24).

The mechanism by which amniotic membrane enhance epithelialization could be attributed to the production of growth factors, and the basement membrane of amniotic membrane facilitates migration of epithelial cells which reinforces the adhesion of basal epithelial cells, and may promote epithelial differentiation^(19,20). Amniotic membrane exerts anti-scarring effect through secreting anti-inflammatory cytokines and suppressing TGF- β signaling at the transcriptional level, leading to down-regulation of several downstream genes that are responsible for scar formation⁽²⁵⁾.

MATERIALS AND METHODS

This study was performed in the Oral and Maxillofacial Surgery Department, College of Dentistry, University of Mosul, Iraq, from 28/2/2013 to 21/6/2013. Twenty, locally bred, 6-8 months old male rabbits were planned to conduct the study. The weight of each rabbit was about 1.5 ± 0.5 kg. The animals were housed in an animal house prepared for that purpose, given free access to water and food, and maintained on a 12-h light-dark cycle.

According to sacrificing time, animals could be divided into four groups:

G1: Animals sacrificed after 3 days.

G2: Animals sacrificed after 1 week.

G3: Animals sacrificed after 2 weeks.

G4: Animals sacrificed after 1 month.

Each one of these groups included two sub groups which are:

Subgroup C: Which included the control group.

Subgroup AM: Which included the study group. For achieving general anesthesia each animal was given intramuscular dose of xylazine base (sedative and muscle relaxant) (5 mg/kg) and ketamine hydrochloride (anesthetic and analgesic) (50 mg/kg) injected into rabbit's thigh muscle⁽¹⁶⁾. The

animal was laid on its ventral side on the surgical board ,the hair was shaved using lotion hair remover, the area was washed with a tap water. The animal was covered with sterile towel exposing dorsal side only. The surgical area was then disinfected by scrapping using piece of gauze with povidone-iodine solution (10 %) before performing the wound. A metal template measuring 10 mm in diameter was placed on the skin and an outline of the template was traced on the skin using a pen marker. The wound was made by excising the skin,within the border of the template. Bilateral full-thickness circular segments approximately 10 mm in

diameter and nearly (3-4) mm in thickness were excised from the back of each rabbit (near to the mid-dorsum area) with a surgical blade (No. 11), one dorsal skin wounding was performed lateral to the midline on right side, another was performed lateral to the midline on left side, (with at least 1 cm the distance between two wounds). The right wound was used as experimental wound and covered with dried amniotic membrane, the left wound was considered as a control wound. All wounds were covered with non adherent moist occlusive gauze⁽¹⁷⁾ Figure (2).

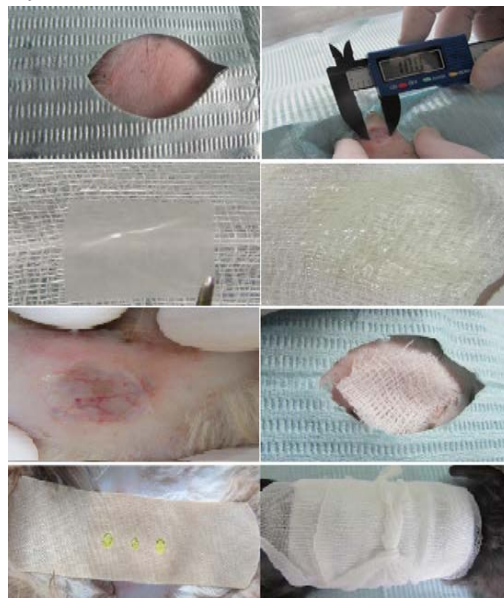

Figure (2).Surgical Procedure

- A: The hair was shaved using lotion hair remover.
- B: Bilateral full-thickness circular segments approximately 10 mm in diameter were excised from the back of each rabbit
- C: The Amniotic Membrane was cut into appropriate size.
- D: The material was put on gauze and moistened with normal saline.
- E: The material was applied to the study wound.
- F: Both control and study wounds were covered with moist occlusive gauze.
- G: Both control and study wounds were covered with strips
- H: A bandage was wrapped around the trunk of animals

Examination used to assess scoring for reepithelialization wich include⁽¹⁸⁾.

Score 0: Reepithelialization at the edge of the wound.

Score 1: Reepithelialization covering less than half of the wound.

At day of sacrifice ,samples were taken and placed in 10% formalin and sent for histopathological study. Histopathological

Score 2: Reepithelialization covering more than half of the wound.

Score 3: Reepithelialization covering the entire wound, irregular thickness.

Score 4: Reepithelialization covering the entire wound, normal thickness.

Statistical analysis was made by using spss 19 computer soft ware program. Data were analyzed by using Mann - Whitney

NPar Test was used to compare means between groups .

In this study the effects of gamma-irradiated amniotic membrane on the epithelialization of the secondary wound sites were assessed. Since the use of gauze dressing is cheaper as compared to other commercial available dressings and is the normal practice for coverage of wound, healing of secondary wound with gamma irradiated amniotic membrane dressing and standard gauze dressing was compared. The results included reepithelialization examination in the four periods of the study as shown in Table (1),Chart (1).

RESULTS AND DISCUSSION

Table 1. Mann-Whitney Statistical Test (p-value) of reepithelialization score Comparing between Control and Amniotic membrane Groups.

Duration	Reepithelialization (p-value)
3Days	1.000
7 Days	0.606
14 Days	0.005*
30 Days	1.000

Significance (*): p value ≤ 0.05

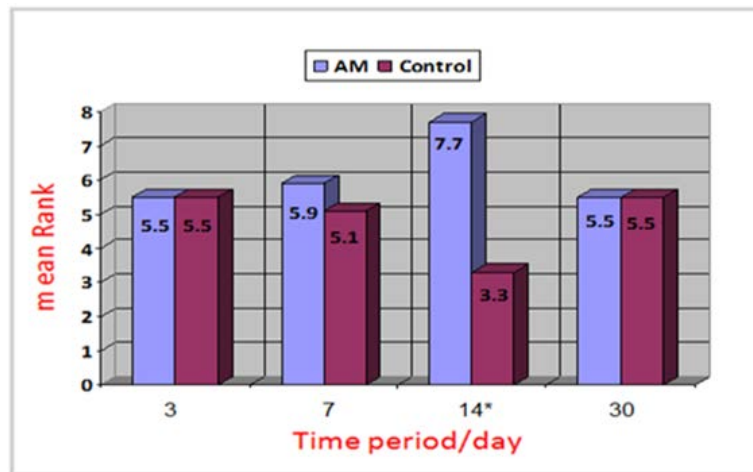


Chart (1) Mean Rank Differences between amniotic membrane group and control group at 3, 7, 14 and 30 Days Respectively For Reepithelialization

In the three days period, there is a minimal

reepithelialization at the wound edge in both groups Figure (3).

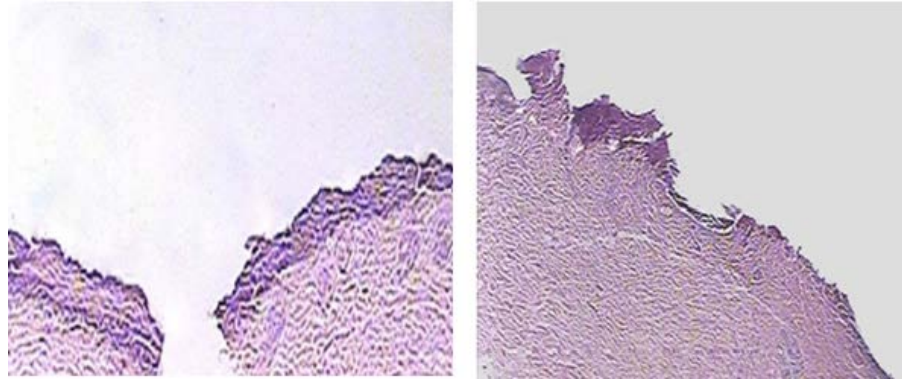


Figure (3): Three Days periods. A: for control group. B: for Amniotic membrane group (Magnification power $\times 100$).

No statistically significant variation in the reepithelialization process between groups at this time. This result agreed with comparative study of Nordback et al., they concluded that the difference in epithelialization was not statistically significant between the dispase de-epithelialized, glycerol cryo-preserved amniotic membrane group and sodium chloride-moistened gauze group at 3 day period⁽¹⁷⁾. A study conducted by Wai-kakul S, et al, (1990) used freeze-dried amniotic membrane applied in the form of split-thickness skin grafts over an area from which skin had been surgically removed. they found that covering the wound with the amniotic membrane had good results in terms of pain reduction, but the promotion of healing were not demonstrated⁽²⁶⁾. In contrast, Woob et al., (2001) investigated the effects of amniotic membrane on epithelial

wound healing and stromal remodelling on eye of the rabbits by creating a wound 6.0 mm in diameter using an excimer laser, one eye was covered by the AM while the other eye served as a control they found that the course of healing was started with a slower initial phase, a faster middle phase, and increasing healing latency towards complete epithelial closure and most of the eyes in the AM group were entirely re-epithelialised by 72 hours after surgery⁽²⁷⁾. Corneal and dermal epithelialisation cannot be stated as equal because corneal wound healing is thought to be a simpler process than when the healing process occurs in the skin. For instance, cornea lacks blood vessels in the cornea⁽²⁸⁾.

In one week period, there was no statistically significant variation in reepithelialization between groups but the degree of reepithelialization of wounds covered by amniotic membrane were better Figure (4).

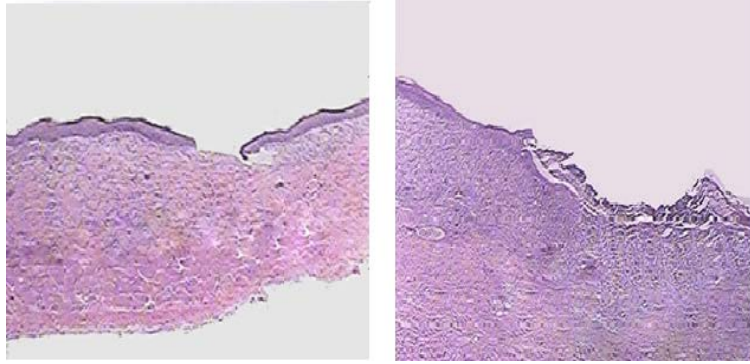


Figure (4): One Week Period. A: for control group. B: for Amniotic membrane group (Magnification power $\times 100$).

This result agreed with comparative study of Nordback *etal.*, they concluded that the epithelialization was somewhat larger in the AM group on days 7 but the difference was not statistically significant⁽¹⁷⁾. In two

weeks period, There was a statistically significant enhancement of epithelialization of amniotic membrane group compared to control group as in Figure (5).

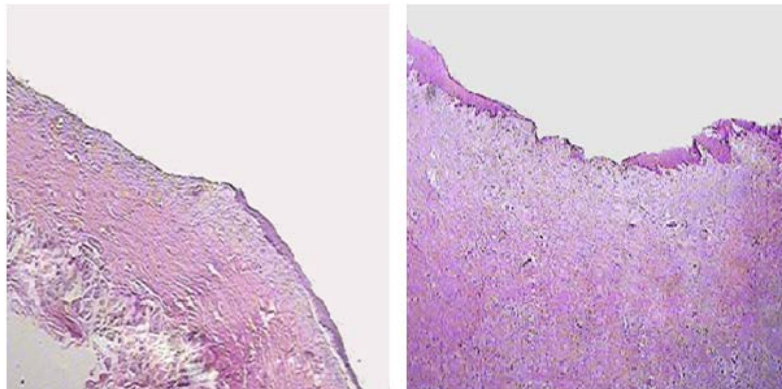


Figure (5): Two Week Period. A: for control group. B: for Amniotic membrane group (Magnification power $\times 100$).

The amniotic membrane has beneficial reepithelialization effects, the AM contains many growth factors and the basement membrane facilitates migration of epithelial cells which reinforces the adhesion of basal epithelial cells, and may promote epithelial differentiation, the AM provides a suitable substrate, such as laminins for rapid attachment of epithelial cells. AM might exert its

wound healing effect by accelerating keratinocyte migration from the wound edge and inducing its differentiation, thereby contributing to the generation of intact epithelium (4,19-21).

Mermet *etal.*, used AM on the treatment of chronic venous leg ulcers, they found that the greatest effect of AM was observed at the 14th day but no significant

effect was seen at the 7th day⁽²²⁾. Insausti *et al.* concluded, although the process was slow, AM application in human patients with post-traumatic wounds inducing the formation of a well-structured epidermis with all relevant layers and restoring skin integrity⁽⁴⁾.

In the one month period, both groups showed complete epithelialization and there was no statistically significant variation in reepithelialization between groups. Both groups showed well-recovered epidermal and dermal layers. The epidermis showed mature differentiation, and the dermal layer showed thick collagen bundle deposition and well-recovered skin appendages. Usually the healing at this period is by far completed and inflammation subsided.

Nordback *et al.*, found that the effect of AM decreases in later stages. they concluded that the difference in epithelialization was not statistically significant between the disperse de-epithelialized, glycerol cryopreserved amniotic membrane group and sodium chloride-moistened gauze group at 21 day period⁽¹⁷⁾.

CONCLUSIONS

Dried Amniotic membrane has properties that are helpful in wound healing. According to this study, the use of amniotic membrane as a dressing in secondary wound to enhance epithelialization is beneficial.

REFERENCES

1. Baskovich B, Sampson EM, Schultz GS, Parnell LK. Wound dressing components degrade proteins detrimental to wound healing. *Int Wound J.* (2008);5: 543–51.
2. Florian Schwarz, Martina J, Monika B, Joerg H. Holstein, Tim P, Martin Oberinger. Soft tissue fibroblasts from well healing and chronic human wounds show different rates of myofibroblasts in vitro. *Mol Biol Rep.* (2013);40:1721–1733.
3. Bello YM, Phillips TJ. Recent advances in wound healing. *J Am Med Assoc.* (2000); 283: 716–8.
4. Carmen L. Insausti, Antonia A, Eva M. Garcí'a-Vizcaí'no, Anna Mrowiec; Mari'a C. Lo'pez-Martí'nez, Miguel Blanquer, Antonio Pin'ero,; Mari'a J. Majado,; Jose' M. Moraleda,; Gregorio Castellanos, Francisco J. Nicola's. Amniotic membrane induces epithelialization in massive posttraumatic wounds. *Wound Repair and Regeneration.* (2010);18 :368–377.
5. Balasubamani, M., Kumar, T.R., Babu, M., (2001). Skin substitutes: a review. *Burns* 27:534–544.
6. Howling, G.I., Dettmar, P.W., Goddard, P.A., Hampson, F.C., Dornish, M., Wood, E.J. The effect of chitin and chitosan on the proliferation of human skin fibroblasts and keratinocytes in vitro. *Biomaterials.* (2001);22:2959–2966.
7. Jayakumar, R., Prabakaran, M., Sudheesh Kumar, P.T., Nair, S.V., Tamura, H. Biomaterials based on chitin and chitosan in wound dressing applications. *Biotechnol. Adv.* (2011); 29:322–337.
8. Rinastiti M, Harijadi, Santoso AL, So-sroseno W. Histological evaluation of rabbit gingival wound healing transplanted with human amniotic membrane. *Int J Oral Maxillofac Surg.* (2006);35:247–251.
9. Niknejad H, Peirovi H, Jorjani M, Ahmadiani A, Ghanavi J, Seifalian AM. Properties of the amniotic membrane for potential use in tissue engineering. *Eur Cell Mater.* (2008);15:88–99.
10. Dua HS, Gomes JA, King AJ, Mahajan VS. The Amniotic Membrane in

- Ophthalmology. Surv Ophthalmol .(2004);49:51-77.
11. Park JH, Jeoung JW, Wee WR, Lee JH, Kim MK, Lee JL.Clinical efficacy of amniotic membrane transplantation in the treatment of various ocular surface diseases. Contact Lens Anterior Eye.(2008); 31:73-80.
12. Parolini O, Soncini M.Human placenta: a source of progenitor/ stem cells? J Reproduktionsmed Endokrinol .(2006); 3: 117–25.
13. Parolini O, Alviano F, Bagnara GP, Bilic G, Buhring HJ, Evangelista M, Hennerbichler S, Liu B, Magatti M, Mao N, Miki T, Marongiu F, Nakajima H, Nikaido T, Portmann-Lanz CB, Sankar V, Soncini M, Stadler G, Surbek D, Takahashi TA, Redl H, Sakuragawa N, Wolbank S, Zeisberger S, Zisch A, Strom SC.Concise review: isolation and characterization of cells from human term placenta: outcome of the first international Workshop on Placenta Derived Stem Cells. Stem Cells. .(2008); 26: 300–11.
14. Koizumi NJ, Inatomi TJ, Sotozono CJ, Fullwood NJ, Quantock AJ, Kinoshita S.Growth factor mRNA and protein in preserved human amniotic membrane. Curr Eye Res .(2000); 20: 173–7.
15. Ghodsieh Paeini-Vayghan, Habibollah P and Hassan N. Inducing of angiogenesis is the net effect of the amniotic membrane without epithelial cells .In J Med Hypotheses Ideas . .(2011);5:16.
16. Yoram Abramov & Emmet Hirsch & Vladimir Ilievski & Roger P. Goldberg & Sylvia M. Botros & Peter K. Sand.Transforming growth factor beta 1 gene expression during vaginal vs cutaneous surgical wound healing in the rabbit.Int Urogynecol J.(2013);24:671–675.
17. P.H. Nordback, S. Miettinen, M. Pelto-Huikko, H. Kuokkanen, R. Suuronen. Amniotic membrane reduces wound size in early stages of the healing process. journal of wound care. .(2012);21901(4) :190-197.
18. . Lopez-Jornet P, Alonso FC and Mez-Garci AF. Evaluation Of Biochemical The Two Cyanoacrylates: An Experimental Study in Rats. Journal of Biomaterials Applications.(2009);24: 197-207.
19. .Mohammad H Samandari,Shahriar Adibi,Ahad Khoshzaban,Sara Aghazadeh,Parviz Dihimi,Siamak S Torbaghan,Saeed H Keshel,Zohreh Shahabi. Human amniotic membrane, best healing accelerator, and the choice of bone induction for vestibuloplasty technique (an animal study).Transplant Research and Risk Management .(2011); 3:1–8.
20. Yogesh Sharma, Anisha Maria, and Preeti Kaur. Effectiveness of Human Amnion as a Graft Material in Lower Anterior Ridge Vestibuloplasty: A Clinical Study. J Maxillofac Oral Surg.(2011);10(4): 283–287.
21. Lee SH, Tseng SC. Amniotic membrane transplantation for persistent epithelial defects with ulceration. Am J Ophthalmol .(1997);123: 303–12.
22. Isabelle Mermet, Nathalie Pottier, Jean Marie Sainthillier, Carole Malugani, Sandrine Cairey-Remonnay, Stéphane Maddens, Didier Riethmuller, Pierre Tiberghien, Philippe Humbert,; François Aubin,. Use of amniotic membrane transplantation in the treatment of venous leg ulcers, Wound Rep Reg. (2007);15:459–464 .
23. Beldon P. Basic Science of Wound Healing. Surgery.(2010); 28(9): 409-412.
24. Bongard FS, Stamos MJ, Passaro E.(1997): Surgery A Clinical Approach.

- 1st edition. Churchill Livingstone Inc. USA, New York; Chapter 8: 69-75.
25. Letko E, Papaliadis DN, Papaliadis GN, Daoud YJ, Ahmed AR, Foster CS . Stevens-Johnson syndrome and toxic epidermal necrolysis: A review of the literature. *Ann Allergy Asthma Immunol.* (2005); 94:419-436.
26. Waikakul S, Chumniprasas K, Setasubun S, Vajaradul Y Bull Hosp Jt Dis Orthop Inst. Application of freeze-dried amniotic membrane: a control trial at the donor site of split-thickness skin grafting.(1990);50(1) :27-34.
27. Woob H-M, M S Kima, O-K Kweonb, D-Y Kimb, T-C Namb, and J H Kima .Effects of amniotic membrane on epithelial wound healing and stromal remodelling after excimer laser keratectomy in rabbit cornea . *Br J Ophthalmol.* (2001);85(3): 345-349.
28. Wilson, S.E., Mohan, R.R.,Mohan, R.R. et al. The corneal wound healing response:cytokine-mediated interaction of the epithelium, stroma, and inflammatory cells. *Prog Retin Eye Res.*(2001);20(5):625–637.