



Assessment of IL-6 in the Oral Mucosal Healing with PerioKIN Hyaluronic 1%® and OzOHEAL-M® in Rabbits

Mohanned Younis Hamid , Ziad H. Deleme , Ahmed Salih Khudhur

Department of Oral and Maxillofacial Surgery, College of Dentistry, Mosul University / Iraq

Article information

Received: August 5, 2021

Accepted: September 26, 2021

Available online: March 20, 2023

Keywords

Immunohistochemistry

IL-6

Hyaluronic acid

Ozonated oil

*Correspondence:

E-mail:

Mohanned.younis@uomosul.edu.iq

Abstract

Aims: To compare the effects of Hyaluronic acid (PerioKIN Hyaluronic 1%)® and ozonated oil (OZOHEAL-M)® on healing after induced wounds in rabbits oral mucosa and to detect the presence of interleukin-6 (IL-6) as a biomarker using immunohistochemistry. **Materials and methods:** The study was conducted on (12) male New Zealand rabbits, randomly divided into two groups (6 animals per group) according to the healing periods (3rd, 7th, and 14th) days. Two incisions were made on the buccal mucosa of each rabbit bilaterally. For the first group, the defects were filled with (PerioKIN Hyaluronic 1%) gel, (OZOHEAL-M) gel was applied for the second group, applied three times daily, two rabbits were randomly selected of each group at the (3rd, 7th, and 14th) days, and biopsies were taken. The biopsy specimens were subjected to Immunohistochemical evaluation to assess wound healing potential utilizing IL-6 as a marker. **Results:** Median scores of IL-6 expression for oral mucosa showed that at day three perioKIN group showed higher expression of the marker but at day seven there was equal and finally at day fourteen there is no expression of IL-6 marker in Ozoheal group, there was a statistically significant difference at all periods for Ozoheal group which means that Ozoheal has less reaction to local tissue response. **Conclusion:** Ozoheal drug is better than perioKIN gel as an anti-inflammatory action and thus could reduce the sequelae related to the inflammatory process.

الخلاصة

الاهداف: تهدف الدراسة الى مقارنة تأثيرات حمض الهيالورونيك (PerioKIN Hyaluronic 1%)® والزيت المعالج بالأوزون (OZOHEAL-M)® على الشفاء وتجديد الأنسجة الرخوة بعد الجروح المستحثة في الأرانب وقياس مستوى التعبير عن الإنترلوكين 6 (IL-6) كمؤشر حيوي باستخدام الكيمياء المناعية. **المواد وطرائق العمل:** أجريت الدراسة على (12) ذكور أرنباً نيوزيلندياً تم تقسيمهم عشوائياً إلى مجموعتين (6 حيوانات لكل مجموعة) حسب فترات الشفاء (الثالث، السابع، الرابع عشر). تم عمل شقين على الغشاء المخاطي الشدقي لكل أرنب بشكل ثنائي. بالنسبة للمجموعة الأولى، تم ملء العيوب بجيل (PerioKIN Hyaluronic 1%)، (OZOHEAL-M) للمجموعة الثانية، تم وضعه ثلاث مرات يومياً، تم اختيار أرنبين عشوائياً من كل مجموعة في (الثالث، السابع، و) الرابع عشر)، وأخذت الخزعات. خضعت عينات الخزعة للتقييم المناعي الكيميائي لتقييم إمكانية التئام الجروح باستخدام IL-6 كعلامة. **النتائج:** أظهرت الدرجات المتوسطة من تعبير IL-6 للغشاء المخاطي للفم أنه في اليوم الثالث أظهرت مجموعة perioKIN تعبيراً أعلى للعلامة ولكن في اليوم السابع كان هناك تساوي، وأخيراً في اليوم الرابع عشر لا يوجد تعبير عن علامة IL-6 في مجموعة Ozoheal، هناك كان فرقاً ذا دلالة إحصائية في جميع الفترات الزمنية لمجموعة Ozoheal مما يعني أن Ozoheal لديه تفاعل أقل مع استجابة الأنسجة المحلية. **الاستنتاجات:** دواء Ozoheal أفضل من هلام perioKIN في العمل المضاد للالتهابات وبالتالي يمكن أن يقلل من التتابعات المرتبطة بعملية الالتئام.

DOI: [10.33899/RDENJ.2021.131056.1127](https://doi.org/10.33899/RDENJ.2021.131056.1127), © 2023, College of Dentistry, University of Mosul.

This is an open access article under the CC BY 4.0 license (<http://creativecommons.org/licenses/by/4.0/>)

INTRODUCTION

A wound is defined as a break in the continuity of the covering skin, and/or lining mucosa. The wound healing process is a complex mechanism involving a cascade of coordinated inflammatory and proliferative steps. Different biomaterials might be required to improve clinical outcomes, and have a potential function in wound healing and regeneration, thereby playing an important role in tissue repair mechanisms in many oral surgical procedures.^(1, 2)

Hyaluronic acid (HA) is a polysaccharide found in the extracellular matrix of connective tissue. The biological action of HA comes from its potential relationship with growth factors, and serves as a lubricant for various body tissues. thus maintaining the structural integrity of tissues. The biocompatible properties of hyaluronic acid being biocompatible, with viscoelastic nature make it unique to be used in several applications such as facilitating scar-less healing and regeneration of incision wounds.^(3, 4)

Ozone therapy is a safe bio-oxidative therapy in which a mixture of oxygen and ozone is administered to obtain therapeutic effects such as; wound healing, post-surgical pain, and many other uses in dental practice.⁽⁵⁾

A biomarkers are an indicators of a particular physiological state, pathogenic processes, or pharmacological responses to any therapeutic intervention. Biomarkers

can be measured objectively, and be accurately reproduced. Many researchers have identified several cellular events and mediators involved in wound healing that can function as biomarkers.^(6, 7)

Immunohistochemistry (IHC) is a method of identifying antigens in tissue sections using antibodies. The main advantage of IHC is the ability to recognize the location of an antigen in a tissue or cell for future study of cell function and characterization of lesions. The basic feature of the IHC process is the detection of a protein, more precisely an epitope that is a part of the protein known as the antigenic determinant, which can be recognized specifically by antibodies.⁽⁸⁾

MATERIALS AND METHODS

Twelve (12) male New Zealand rabbits, three to four months in age, and 1.2~1.4 Kg in weight were included. They were kept in clean cages and housed in a standard environment (a temperature of 18~24°C). They were fed equal amounts of standard food (grass and fresh vegetables) and water. Their health was monitored throughout the study. The rabbits were randomly divided into two experimental groups according to the tested material used to cover the wound postoperatively, the tested agents included the following: PerioKIN Hyaluronic 1%[®] gel (LABORATARIOS KIN S.A., Barcelona - Spain) contains 1% Hyaluronic acid and 0.2% Chlorhexidine DG, and excipients. And O3OHEAL-M[®] gel (Advanced Pharma Care, Jordan) contains

Ozonated Sunflower (Seed Oil), Hydrogenated Vegetable Oil, and Propylene Glycol. The surgical procedures followed a standard protocol used at the Department of Oral and Maxillofacial Surgery - College of Dentistry / Mosul University under ethic registration number UoM.Dent/A.L.8/21 in 19-1-2021. To achieve general anesthesia, each rabbit was given a 40 mg/Kg ketamine intramuscular injection in the thigh muscle, mixed with xylazine 4 mg/kg (as a muscle relaxant). After anesthesia, the surgical field in the oral cavity was disinfected by Chlorhexidine Gluconate 0.2%. Two incisions were made on the anterior buccal mucosa for each rabbit bilaterally, 0.5 cm in length, and 2 mm (0.2 cm) in depth, using blade no.15., measured by a Vernier, all wounds were intentionally left to heal by secondary intention.

One ml of each agent was applied three times daily directly to the wound using a disposable tip with a blunt cannula connected to a syringe, for the first group, the defects were covered with (PerioKIN Hyaluronic 1%) gel, applied three times daily. O3OHEAL-M gel was used for the second group, also applied three times daily. Immunohistochemical Staining Technique for Paraffin sections: De-paraffinization and hydration of tissue sections using xylenes and graded alcohol series. Rinsing for (5 minutes) in tap water. incubate the sections for (30 minutes) in (0.3% H₂O₂) for quenching of endogenous

peroxidase enzyme activity. Washing in buffer solution for (5 minutes). Incubate the sections for (1 hour) at (37°C) with Blocking Serum, Blotting excess Blocking Serum from the sections. Incubating the sections for (1 hour) at (37°C) or Overnight at (4°C) with primary antibody diluted in Phosphate Buffered Saline buffer. washing the slides for (3 minutes) in PBST buffer solution. Incubate the sections for (1 hour) at (37°C) with poly- HRP Goat Anti-Rabbit IgG. Wash the slides for (3 minutes) in PBST buffer solution. Incubate the sections in DAB working solution until the desired stain intensity develops. Rinse the sections using tap water. Counterstaining, clearing, and mounting. To analyze the data of IHC, including the value of certain diagnostic biomarkers or any molecular expression, the results must be expressed numerically for statistical analysis. many quantification methods are available and can be widely used were reviewed. The stained tissue sections were analyzed by a light microscope. In order to avoid possible errors, the data were analyzed by two independent expert pathologists, up to five high-power fields and each sample was randomly selected. Damaged tissue spots or those containing staining artifacts, or unclear histology were excluded from the analysis. The scoring system was used for IL-6 staining intensity evaluation⁽⁹⁻¹²⁾ as shown in (Table 1). The median and inter-quartile range were used to present the data, and a non-parametric test (Mann-Whitney U test) was used for statistical analysis

because we have two independent samples that do not follow a normal distribution. A

P-value less than 0.05 was considered significant.

Table (1): IHC grading criteria to evaluate the expression of IL-6 subjectively. Tripathy *et al.*, (2018).

Score	Staining intensity
0 negative	No staining observed
+1 negative	Incomplete, faint/barely staining
+2 equivocal	Weak to Moderate Staining
+3 positive	Complete, Intense Staining

RESULTS

During this study, all rabbits survived and tolerated the experimental procedure and recovered without any postoperative complications such as bleeding or infection of the wound. Median scores of IL-6 expression for oral mucosa on 3rd, 7th, and 14th days after incisions as compared between perioKIN group and Ozoheal group showed that at day three perioKIN group showed higher expression of the marker but at day seven there was high scores for Ozoheal group and finally at day fourteen there is no expression of IL-6 marker in Ozoheal group, so there was a statistically significant difference at all

periods for Ozoheal group as shown in (Figure 1 and Table 2). For more details (Figures 2 and 3) showed photomicrograph of oral mucosa for day 3 of the perioKIN group with moderate positive reaction (++), And the Ozoheal group showed mild positive reaction (+) of IL-6 expression to immunohistochemistry in the submucosa at the site of the wound, (Figure 4 and 5) showed day 7 with mild positive reaction (+) for perioKIN group and shows moderate positive reaction (++) for another group, (Figures 6 and 7) showed day 14 with moderate positive reaction (++) of IL-6 expression for perioKIN group and negative reaction (-) for the ozoheal group.

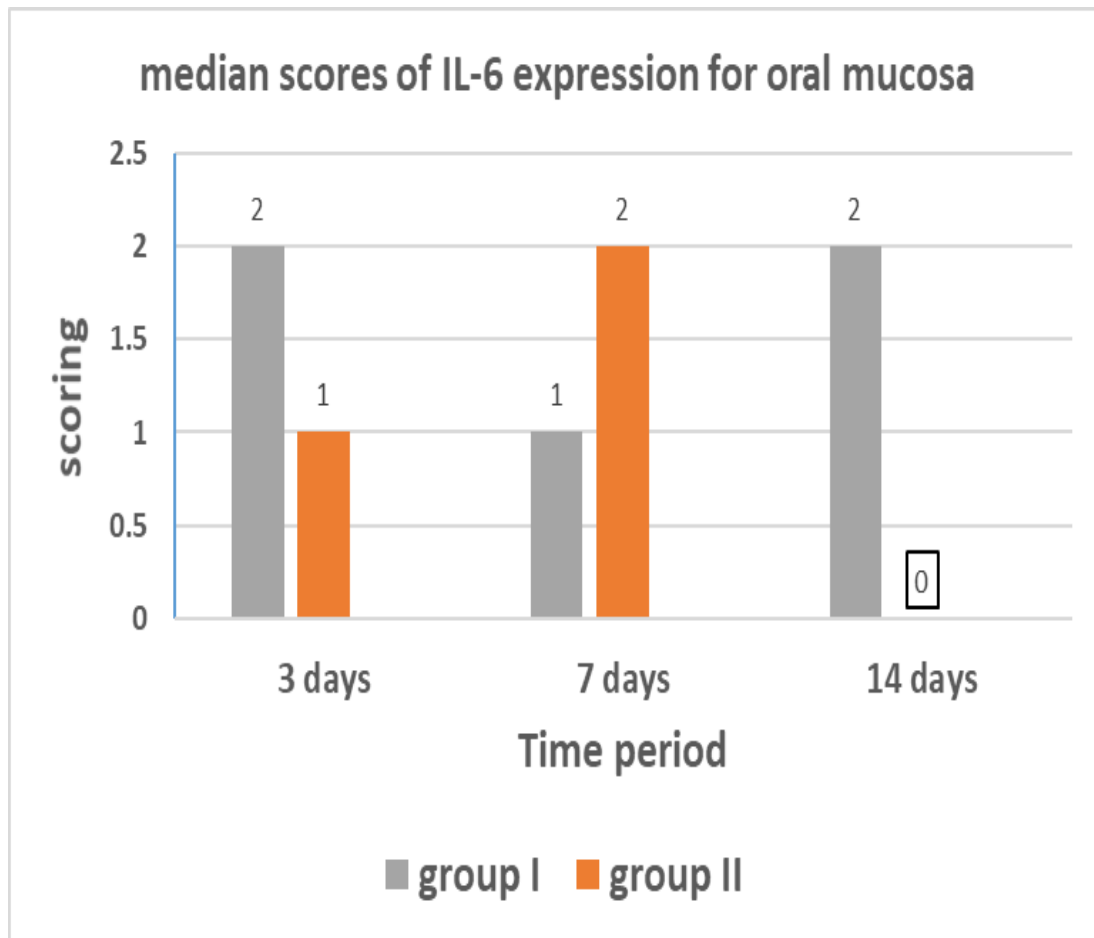


Figure (1): median scores of IL-6 expression for oral mucosa on 3rd,7th, And 14th Days After Incisions. group 1= perioKIN, group 2= Ozoheal.

Table (2): Comparison of IL-6 expression for the oral mucosa (Mann-Whitney U Test).

Days	(P-value)
On the third day	
Group I day3 vs Group II day3	p< 0.001 (0.0001) Highly-significant
On the seventh day	
Group I day7 vs Group II day7	p< 0.01 (0.005) Highly-significant
On the fourteenth day	
Group I day14 vs Group II day14	p< 0.001 (0.0001) Highly-significant

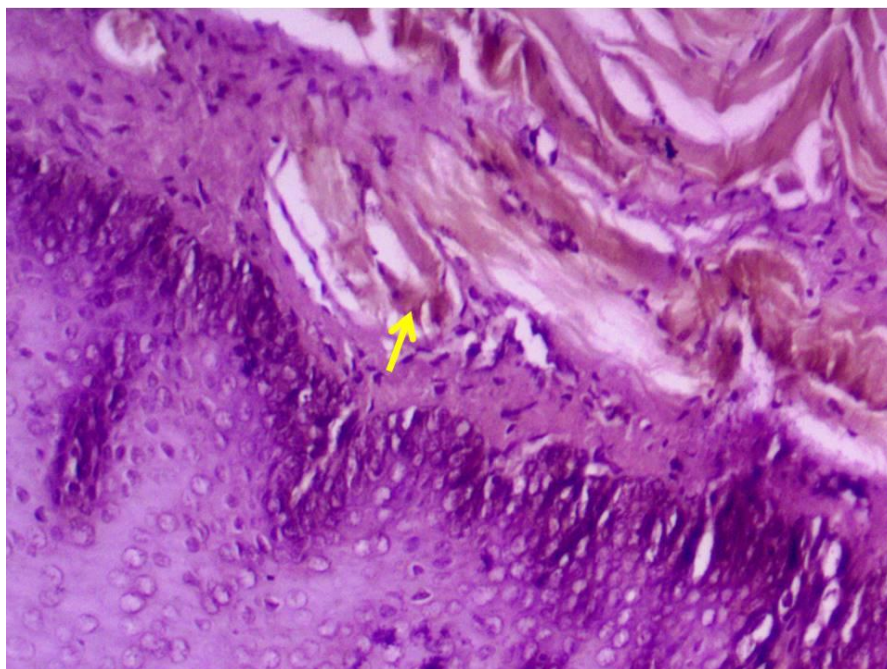


Figure 2: photomicrograph of oral mucosa of group I (3 days) shows moderate positive reaction (+2) of IL-6 expression to immunohistochemistry in the submucosa (arrow) at the site of wound. IHC for IL-6, 400X.

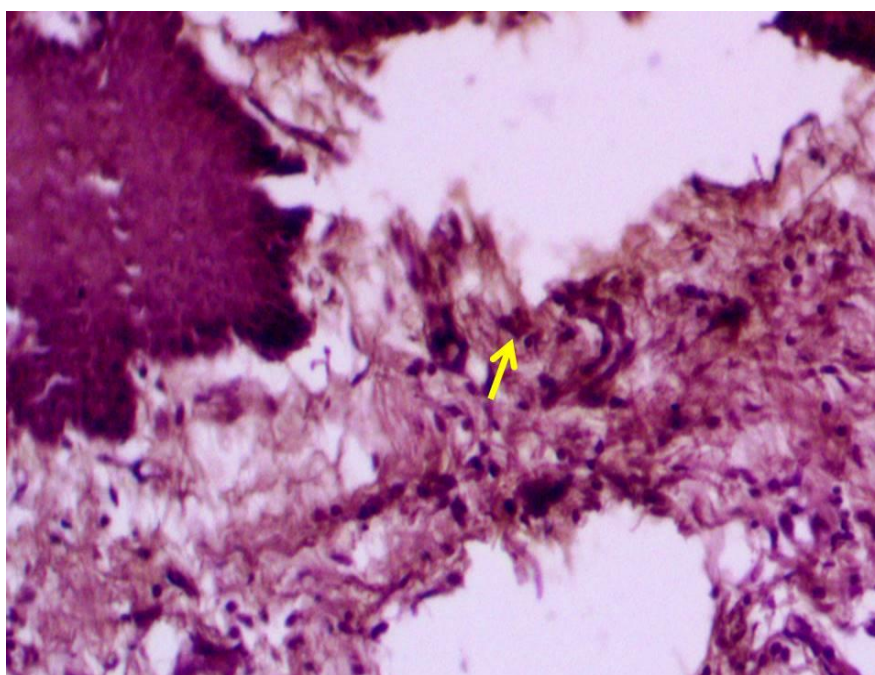


Figure 3: photomicrograph of oral mucosa of group II (3 days) shows mild positive reaction (+1) of IL-6 expression to immunohistochemistry in the submucosa (arrow) at the site of wound. IHC for IL-6, 400X.

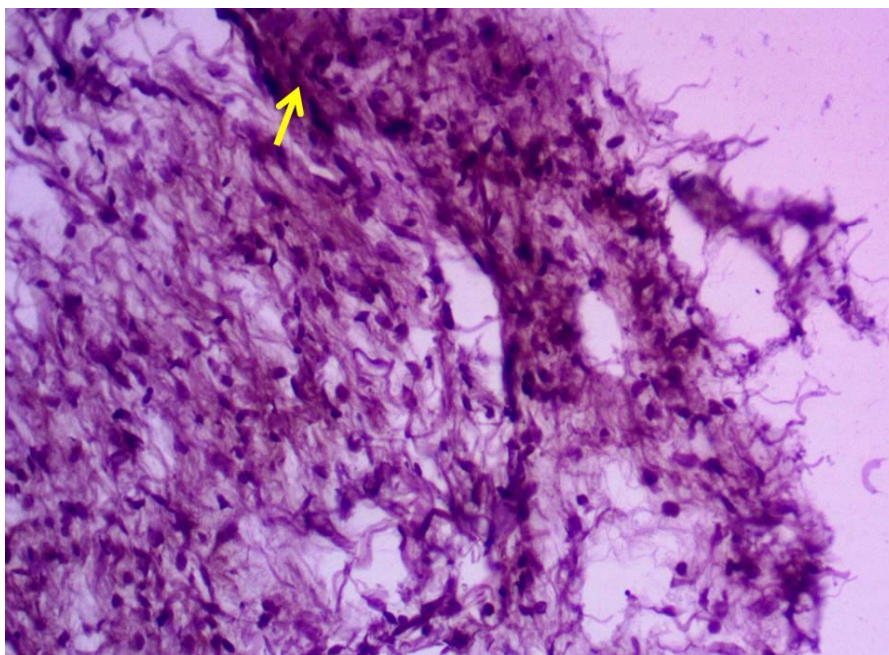


Figure 4: photomicrograph of oral mucosa of group I (7 days) shows mild positive reaction (+1) of IL-6 expression to immunohistochemistry in the submucosa (arrow) at the site of wound. IHC for IL-6, 400X.

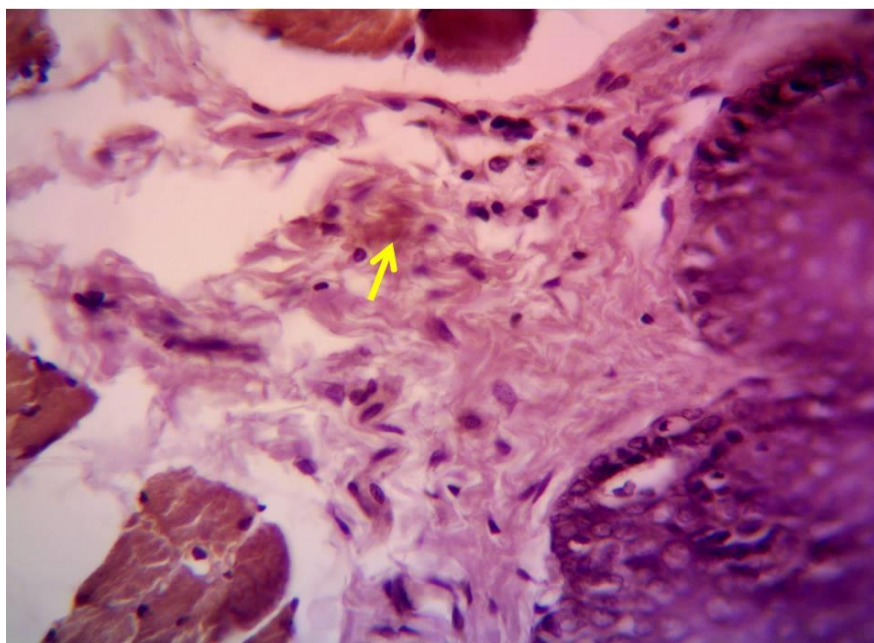


Figure 5: photomicrograph of oral mucosa of M2 group (7 days) shows moderate positive reaction (+2) of IL-6 expression to immunohistochemistry in the submucosa (arrow) at the site of wound. IHC for IL-6, 400X.

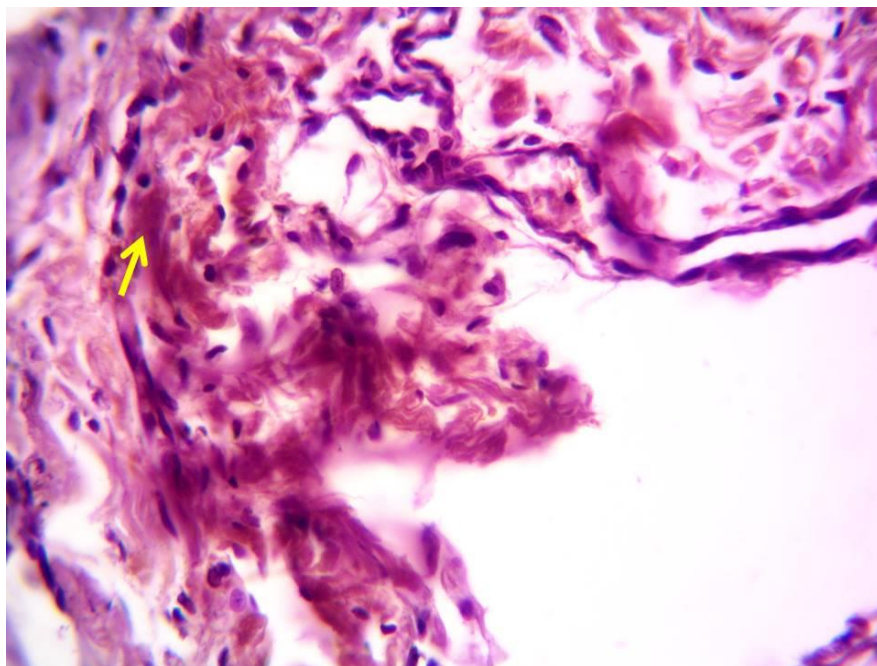


Figure 6: photomicrograph of oral mucosa of M1 group (14 days) shows moderate positive reaction (2+) of IL-6 expression to immunohistochemistry in the submucosa (arrow) at the site of wound. IHC for IL-6, 400X.

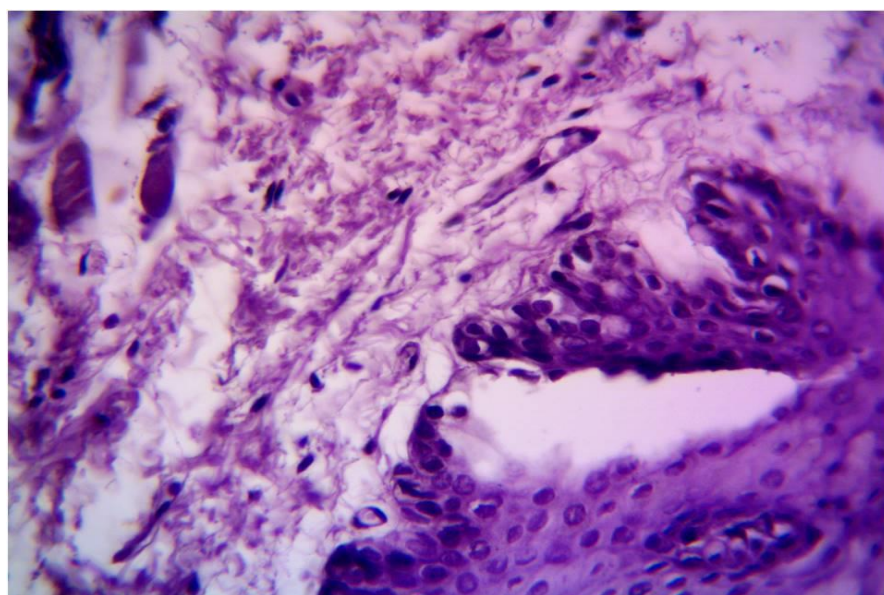


Figure 7: photomicrograph of oral mucosa of M2 group (14 days) shows negative reaction (0) of IL-6 expression to immunohistochemistry in the submucosa at the site of wound. IHC for IL-6, 400X.

DISCUSSION

IHC is an invaluable validation tool for biomarker detection. However, considering the excessive number of existing studies proposing novel IHC biomarkers, markers validated in several clinical cohorts are extremely few, stressing the need to raise quality standards for clinical biomarker studies. Even if the results can be reproduced, the transition towards a routinely used marker is complex. For a new factor to become of potential value in the clinic, it has to add an important value compared with other already used factors. Moreover, it also has to be taken into account in which patient material the factor was analyzed and if it fits with the population where it potentially will be used. To perform and reproduce a multitude of studies for the same marker, a specific antibody, and a standardized antibody validation workflow is crucial. We agree with the proposal recently done⁽¹³⁾ Although IL-6 is an important proinflammatory cytokine closely implicated in the progression of the inflammatory process,^(14,15) high concentrations of pro-inflammatory cytokines inhibit the migration of epithelial cells and gingival fibroblasts, and enhance the expression of TNF- α and IL-1 β at the wound site, thereby reducing cell survival and delaying wound closure.⁽¹⁶⁾ The proinflammatory cytokines proved to be markers for the very early injury interval of up to few hours. The first reactivity increase

was observed for IL-1 β , IL-6, and TNF- α almost simultaneously after 15–20 min. A distinct expression could be determined after about 1–1.5 h. The acute phase stimulator IL-6 was characterized by the longest persistence. Cytokine expression was mainly cell-bound or interstitial and sometimes combined with a more diffuse up-regulation which could be seen as a correlate of excreted mediators within the intercellular space. The results were independent of the topographic region of the mucosal wounds. Moreover, IL-6 marker demonstrated a reappearance of reactivity in a time interval of days. There is correspondence to literature results, where IL-6 and TNF- α also be seen in the chronic granulation tissue of the mouse after a wound age of up to 28 days in macrophages⁽¹⁷⁾. The distribution pattern of proinflammatory mediators in normal human skin is described as nonuniform. Nevertheless, there is accordance in the basics in the expression pattern of IL-1 β , IL-6, and TNF- α in normal skin⁽¹⁸⁾ which we found and those of most literature information, predominantly a slight (up to negative) preexisting, frequently granular or intercellular formed expression of mediators.

CONCLUSION

Ozoheal drug is considered to be better than perioKIN gel in the treatment of wound healing also to accelerate the healing process as it is regarded as a

reducing factor in anti-inflammatory action and thus could reduce the sequelae related to the inflammatory process and promote healing in a shorter time.

REFERENCES

1. Armitage J., and Lockwood S. Skin incisions and wound closure. *Surgery* (Oxford). 2011; 29(10): 496-501.
2. Tejiram S., Kavalukas SL., Shupp JW., and Barbul A. Chapter 1- Wound healing. In: Ågren MS, ed. *Wound Healing Biomaterials*. Woodhead Publishing. 2016; pp. 3-39.
3. Liu Z., Jiao Y., Wang Y., Zhou C., and Zhang Z. Polysaccharides-based nanoparticles as drug delivery systems. *Advanced drug delivery reviews*. 2008; 60(15): 1650-1662.
4. Casale M., Moffa A., Vella P., Sabatino L., Capuano F., Salvinelli B., Lopez MA., Carinci F., and Salvinelli F. Hyaluronic acid: Perspectives in dentistry. A systematic review. *International journal of immunopathology and pharmacology*. 2016; 29(4): 572–582.
5. Pattanaik B., Pattanaik S., Naitam D. N., Jetwa D., Manglekar S., and Dani A. Ozone therapy in dentistry: A literature review. *Journal of Interdisciplinary Dentistry*. 2011; 1(2): 87.
6. Shah JM., Omar E., Pai DR., Sood S. (2012). Cellular events and biomarkers of wound healing. *Indian Journal of Plastic Surgery*. 45(2): 220–228.
7. Patel S., Maheshwari A., and Chandra A. Biomarkers for wound healing and their evaluation. *Journal of wound care*. 2016; 25(1): 46-55.
8. Ramos-Vara JA. Chapter 5- Principles and Methods of Immunohistochemistry. In: Gautier J. *Drug Safety Evaluation: Methods and Protocols*. Methods in molecular biology (Clifton, N.J.). 2017; pp. 115-128.
9. Choudhury KR., Yagle KJ., Swanson PE., Krohn KA., and Rajendran JG. A robust automated measure of average antibody staining in immunohistochemistry images. *The journal of histochemistry and cytochemistry: official journal of the Histochemistry Society*. 2010; 58(2): 95–107.
10. Fedchenko N., and Reifenrath J. Different approaches for interpretation and reporting of immunohistochemistry analysis results in the bone tissue - a review. *Diagnostic pathology*. 2014; 221(9): 1-12.
11. Kim SW., Roh J., and Park CS. Immunohistochemistry for Pathologists: Protocols, Pitfalls, and Tips. *Journal of pathology and translational medicine*. 2016; 50(6): 411–418.
12. de Oliveira PA, de Pizzol-Júnior JP, Longhini R, Sasso-Cerri E, Cerri PS. Cimetidine Reduces Interleukin-6, Matrix Metalloproteinases-1 and -9 Immunoexpression in the Gingival Mucosa of Rat Molars With Induced Periodontal Disease. *Journal of periodontology*. 2017; 88(1): 100–111.
13. Howat, W.J., Lewis, A., Jones, P., Kampf, C., Ponten, F., van der Loos, C.M., Gray, N., Womack, C., Warford, A., 2014.

- Antibody validation of immunohistochemistry for biomarker discovery: Recommendations of a consortium of academic and pharmaceutical-based histopathology researchers. *Methods*.
14. Li Y, Chi L, Stechschulte DJ, Dileepan KN. Histamine-induced production of interleukin-6 and interleukin- 8 by human coronary artery endothelial cells is enhanced by endotoxin and tumor necrosis factor-alpha. *Microvasc Res* 2001;61:253-262.
 15. da Fonseca TS, da Silva GF, Tanomaru-Filho M, Sasso-Cerri E, Guerreiro-Tanomaru JM, Cerri PS. In vivo evaluation of the inflammatory response and IL-6 immunoexpression promoted by Biodentine and MTA Angelus. *Int Endod J*. 2016;49:145-153.
 16. Basso F G, Pansani T N, Turrioni A P S, et al. Tumor necrosis factor-alpha and interleukin (IL)-1b, IL-6, and IL-8 impair in vitro migration and induce apoptosis of gingival fibroblasts and epithelial cells, delaying wound healing. *J Periodontol* 2016; 87: 990–996.
 17. I. Appleton, A. Tomlinson, P.R. Colville-Nash, D.A. Willoughby, Temporal and spatial immunolocalization of cytokines in murine chronic granulomatous tissue. Implications for their role in tissue development and repair processes, *Lab. Invest.* 69 (1993) 405–414.
 18. Wolfgang Grellner, Time-dependent immunohistochemical detection of proinflammatory cytokines (IL-1 β , IL-6, TNF- α) in human skin wounds. *Forensic Science International* 130 (2002) 90–96.
 19. Tripathy K, Mishra A, Singh AK, Panda PL, Mahapatra A, Lenka A.. Immunocytochemistry using Liquid-based Cytology: A Tool in Hormone Receptor Analysis of Breast Cancer. *Journal of cytology*. 2018; 35(4), 260–264.