

# Orthodontic Treatment of Unilateral Impacted Complete Transposed Maxillary Canine and Impacted Dilacerated Maxillary central incisor

**Hakam H Sabah**  
BDS, MSc (Lec.)

**Department of Pedodontics, Orthodontics and Preventive**  
College of Dentistry, University of Mosul

**Saba H. Al-Zubaidi**  
BDS, MSc (Assist Prof.)

**Department of Pedodontics, Orthodontics and Preventive**  
College of Dentistry, University of Mosul

**Omar H. Alluazy**  
BDS, MSc (Lec.)

**Department of Pedodontics, Orthodontics and Preventive**  
College of Dentistry, University of Mosul

## الخلاصة

**الاهداف :** تقديم حالة تم التدخل فيها جراحيا لإظهار الضاحك الأول الأيسر العلوي المعقوف والمطمور سلفا متبوعا بعلاج تقويمي لبزوغه الى موضعه الطبيعي. بالإضافة الى تدخل جراحي اخر للنانب الأيسر العلوي متبوعا بتغيير موضعي للضاحك الثاني وللنانب العلوي. **النتائج :** هذه المقالة وصفت الحالة العلاجية لمريضة في عمر المراهقة ذات ضاحك أول أيسر علوي وناب مطمورين سلفا بالإضافة الى تغيير موضعي لضاحكها الثاني والنانب. الضاحك الأول الضاهر تم علاجه تقويميا و انبثاقه ضمن القوس الفكي. ثم تم التدخل جراحيا لإظهار الناب الأيسر وتحريكه تقويميا ضمن سقف الحلق الصلب بجلبه وحشيا الى موضعه الطبيعي. **الاستنتاجات :** تغيير موضع الاسنان الامامية المطمورة انيا غير شائع ويخلق تحديا لطبيب الاسنان. التشخيص المبكر ومعالجة اضطرابات بزوغ الاسنان ذو فائدة جمالية ووظيفة في النتيجة.

## ABSTRACT

**Aims:** The purpose of this article was to present a case of surgical exposure and orthodontic reposition of impacted dilacerated maxillary left central incisor. Also surgical exposure of impacted maxillary left canine followed by orthodontic treatment of canine-lateral incisor complete transposition. **result :** this article describe the treatment of a teenager girl who had impactions of the maxillary left central incisor and canine as well as canine-lateral incisor transposition. The dilacerated impacted central incisor was uncovered and orthodontically extruded into the dental arch. Then the impacted canine was surgically exposed and orthodontically moving the tooth palately then distally to brought it into its normal position. **Conclusion :** concurrent impaction and transposition of maxillary anterior teeth is uncommon and poses a challenge for the dentist. Early diagnosis and management of eruption disturbances give us both esthetic and functional outcome benefits.

**Key words:** Impaction, canine-lateral incisor transposition, dilacerations, surgical exposure.

Sabah HH., Al-Zubaidi SH. Alluazy OH. Orthodontic Treatment of Unilateral Impacted Complete Transposed Maxillary Canine and Impacted Dilacerated Maxillary central incisor  
Case report) *Al-Rafidain Dent J.* 2017;17(1):58-67.

**Received:** 10/3/2013 **Sent to Referees:** 25/3/2013 **Accepted for Publication:** 9/4/2014

## INTRUDUCTION

Tooth transposition is an anomaly in the position of teeth where two teeth of the

same quadrant change their position in the dental arch.<sup>(1)</sup> The maxillary permanent canine is the most frequently involved tooth<sup>(2,3)</sup>, changing its eruption place with

first premolar, less often with the lateral incisor.<sup>(4)</sup>

Tooth transposition can be complete when both the tooth crown and the root are transposed, or incomplete, when only the clinical crown is transposed but the root apex remains in relatively normal position<sup>(5)</sup>. A possible explanation for tooth transposition would be an exchange in position between developing tooth buds, also genetic or hereditary factor can play a role<sup>(6)</sup>, other causes include trauma, mechanical interference, bone disease, tumors, or cysts.<sup>(7)</sup>

Moving transposed teeth to their normal positions is quite challenging because this requires bodily movement and translation of one tooth to pass another tooth. This procedure may cause damage to the teeth and the supporting structure.<sup>(8)</sup>

The term "dilacerations" refers to an angulation or sharp bend or curve, in the root or crown of the formed tooth.<sup>(9)</sup> Dilacerations is one of the causes of permanent central incisor eruption failure. The cause of incisor dilacerations may be

due to traumatic injury to the primary predecessors<sup>(10)</sup>, or due to ectopic development of the tooth germ.<sup>(11)</sup>

In this article, a case was presented to demonstrate an impaction of maxillary left dilacerated central incisor and canine in addition to complete canine-lateral incisor transposition. An unconventional orthodontic approach for treatment was used to accomplish the desired correction.

### **Case report:**

A female patient 14 years old visited Orthodontic Department at College of Dentistry –University of Mosul\_ with the chief complaint of un erupted maxillary left central incisor and canine with the history of extracted deciduous tooth. She had no history of dental trauma. Intra oral examination showed an angle class I molar relationship bilaterally, class I canine relationship on the right side, missing upper left central incisor and canine, (2.5mm) of over jet and (2mm) of overbite . pretreatment periapical, and panoramic radiograph (Figure 1 A and B) demonstrated dilacerated impacted maxillary left central incisor and impacted canine with complete canine-lateral incisor transposition .

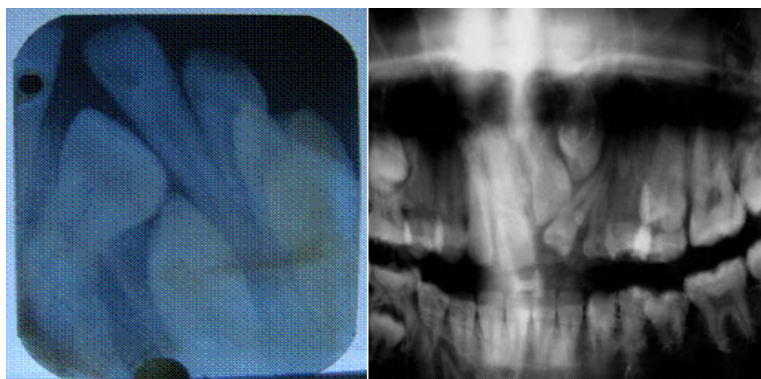


Figure ( 1): (A): pretreatment periapical radiograph( B): Pretreatment panoramic radiograph

Potential benefits and risks of various treatment plans were explained to the patient and her parents. The decided treatment plan included orthodontic extrusion of maxillary dilacerated central incisor and orthodontic reposition of impacted canine and lateral incisor following staged exposure and traction. A fixed orthodontic appliance was bonded using 0.022 X0.028 inch slot Roth

bracket ( Denturam Co./Germany) and 0.016 inch round NiTi wire (IOS Co./USA) was placed for alignment and leveling. Later this wire was replaced by 0.016 inch stainless steel followed by 0.018 inch stainless steel wires (IOS co./USA). Then, distalizing the lateral incisor was carried out using power chain elastic to regain space for the central incisor (Figure 2 A and B).

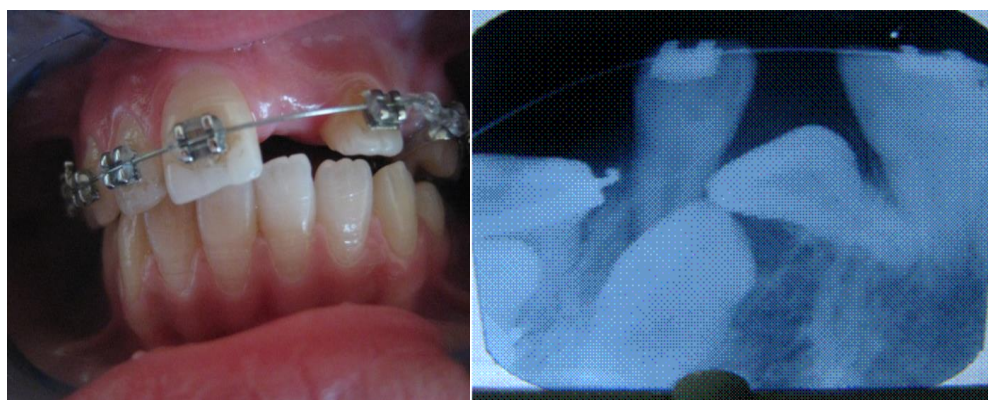
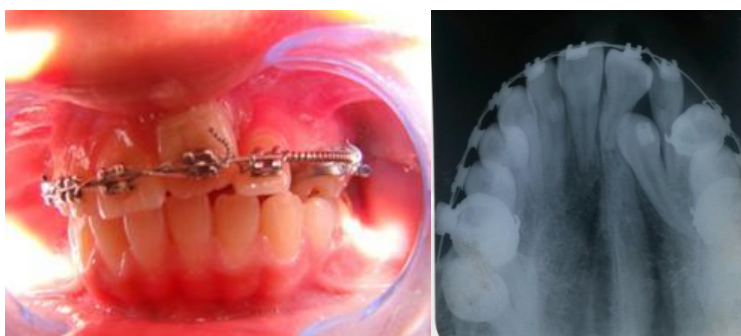

Figure (2): (A): Retraction of lateral incisor(B):Periapical view for retraction of lateral incisor

Once the space was gained, the central incisor exposed surgically. A 0.022 inch slot stainless steel bracket was bonded on the labial surface of central incisor. All brackets were ligated in the form of figure 8 with

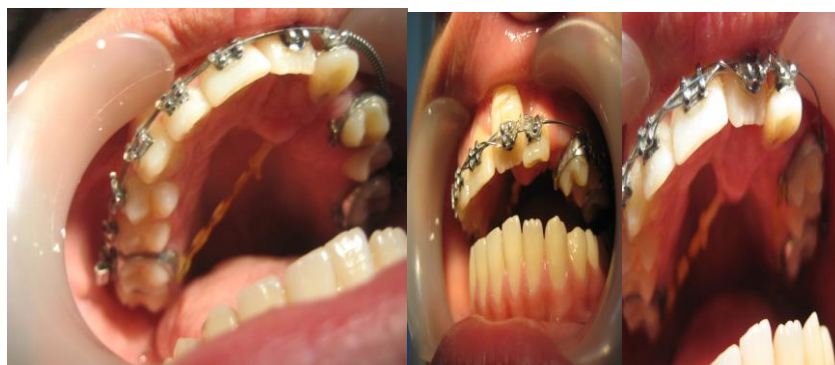stainless steel ligature wire to increase the anchorage in this side. then extrusion of the tooth was carried out using power chain elastic and the tooth orthodontically aligned into its normal position (Figure 3 A and B).



Figure(3): (A): Extrusion of central incisor(B): occlusal view for extrusion of central incisor

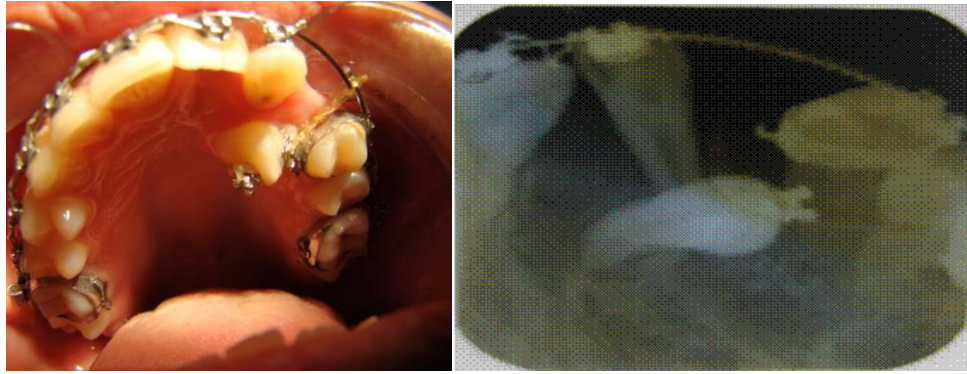During extrusion of impacted dilacerated left central incisor, open coil was used between left lateral incisor and left first premolar as space maintainers. Surgical exposure of **palatally** impacted canine was carried out and 0.022 inch slot stainless steel bracket bonded on its lingual surface. Power chain elastic attached on the lingual bracket to move canine palatally toward the other

side (right side) ( Figure 4 A and B), after the maxillary canine reached a position palatal enough to bypass the lateral incisor without damage and then , 0.022 inch slot stainless steel bracket was bonded on the labial surface and power chain elastic attached to the bracket to move the canine buccally and distally (Figure 5 A and B) .



Figure(4): (A) moving canine palatally (step 1) (B): moving canine palatally (step 2)

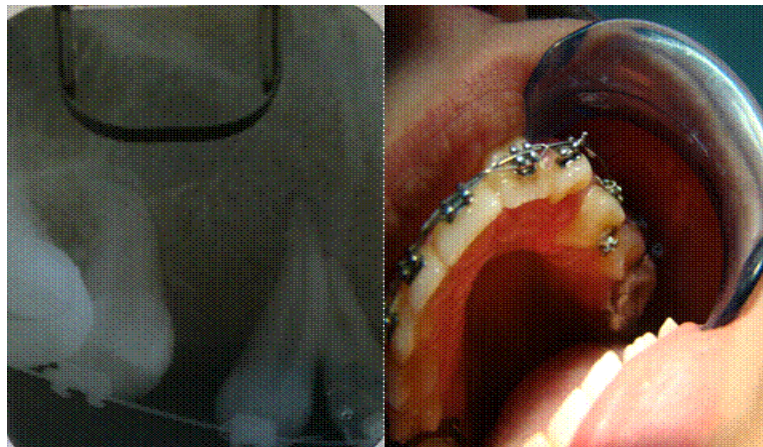




Figure(5): (A): moving the canine buccally(B): periapical view of moving the canine buccally

Extraction of the maxillary left first premolar was planned to create enough space for canine. When canine reach its final position, 0.014 inch NiTi wire was used for

initial leveling and alignment of canine (Figure 6) followed by continuous 0.016X0.022 inch NiTi arch wire (IOS Co./USA) to finish leveling.



Figure(6): initial leveling and alignment of canine

Then the whole dental arch stabilized with 0.019X0.025 inch stainless steel arch wire (IOS Co./USA) (Figure 7 ). Then, after retention period of (2 months), orthodontic

appliance was removed (Figure 8), and composite restoration was done for the labial surface of maxillary left central incisor (Figure 9).

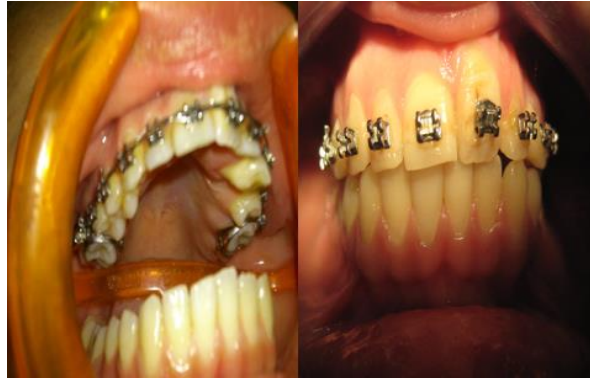
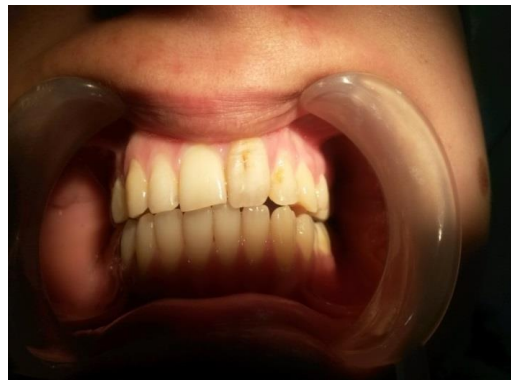
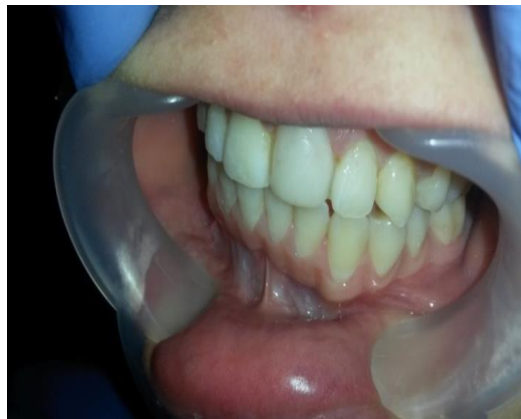Figure (7): Final position of the canine after retention



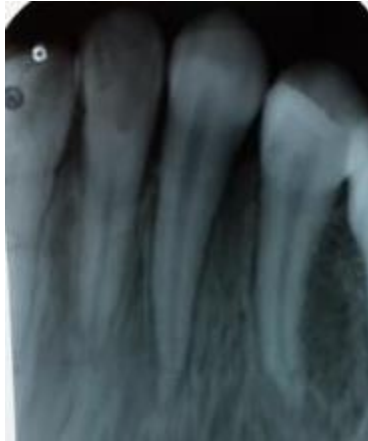Figure( 8): Post treatment photograph



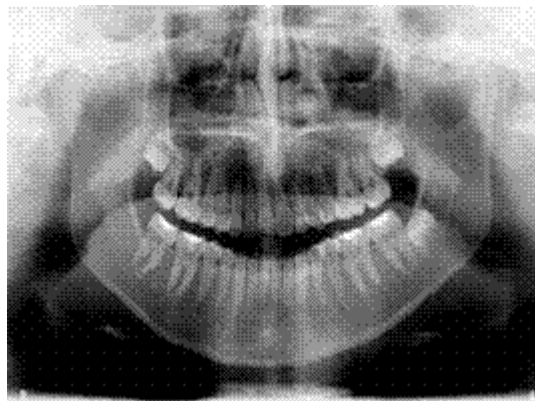
Figure(9): Central incisor after restoration

Post treatment panoramic and perapical radiographic finding shows normal position of the left maxillary central-lateral incisors and canine, class I molar relationship on both sides. The radiographic

view demonstrates normal alveolar contours and support. No sign of root resorption or any other damage to the central-lateral incisors and canine was seen (Figures 10, 11).



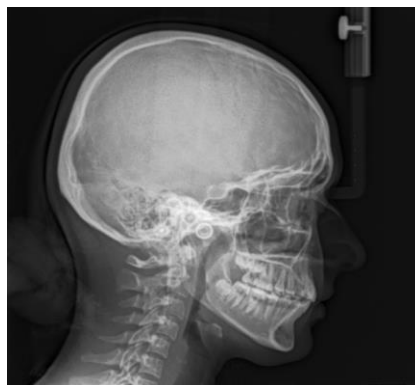Figure(10): Post treatment periapical radiograph



Figure( 11): Post treatment panoramic radiograph

Post retention cephalometric measurements show that the skeletal pattern remained normal and that the treatment

approach and objectives were appropriate (Figure 12) (Table 1) .



Figure( 12): Post treatment cephalometric radiograph

Table (1): Post treatment cephalometric measurements.

Label	Relation	Unit	Value
S-N-A	S-N-A	Degree	79.9
S-N-B	S-N-B	Degree	77.1
A-N-B	A-N-B	Degree	2.8
teeth-skull	Occlusal Plane, S-N	Degree	17.0
mandibular plane angle	Mandibular Plane, S-N	Degree	37.0
maxillary incisor position	Upper Incisor Axis, N-A	Degree	19.0
interincisal angle	Lower Incisor Axis, Upper Incisor Axis	Degree	123.0
Go-Gn, S-N	Go-Gn, S-N	Degree	35.0
N-B, Lower Incisor Axis	N-B, Lower Incisor Axis	Degree	145.0
Lower Incisor to NB	Lower incisor Axis, N-B	Degree	35.0
anterior cranial base	S-N	Mm	65.1
Upper incisor NA distance	Is, N-A	Mm	3.5
Lower incisor,N-B distance	Ii, N-B	Mm	5.6
Pog to NB	Pog ,N-B	Mm	1.0

## DISCUSSION

Among dentitional anomalies, tooth transposition is considered one of the most difficult to manage. Treatment option for these transposed teeth include alignment of teeth in their transposed positions, correction of the teeth to their normal position, and extraction of one or both transposed teeth.<sup>(12)</sup> Correction was not recommended for the teeth with complete transposition<sup>(13)</sup>, few

cases of correction of complete transposition have been reported.<sup>(14-16)</sup> Impaction of maxillary anterior teeth can be a challenging orthodontic problem. Several reports indicated an impacted tooth can be brought into proper alignment in the dental arch.<sup>(17-19)</sup> Simultaneous impaction of dilacerated maxillary incisor with teeth transposition is a rare clinical situation with diverse therapeutic approaches. In this case, making



an appropriate treatment plan for the impacted teeth and the transposed teeth. The treatment plan including complete correction of the impaction and the transposition was regarded as the ideal solution.

The sufficiency of the buccolingual width of the supporting alveolar bone is an important aspect when moving two adjacent teeth in different directions. Compression and friction during correction can cause iatrogenic damage to the teeth (such as root resorption) and periodontal tissues (such as clefting and recession of gingival tissue). The buccolingual width of the alveolar bone of this patient was sufficient and the maxillary left canine had not erupted. Our results showed clinically acceptable periodontal conditions with some palatal gingival recession after treatment with no obvious root resorption was found on central, lateral incisors or canine as seen from periapical radiograph (roots did not get obvious shorting during the orthodontic treatment) (Figure 10).

The total treatment time of 3 years (including retention time) was relatively long yet acceptable considering the absolute correction of the alteration.

### **CONCLUSION**

This rare and severe positional anomaly known as transposition is an orthodontic challenge. Its correction involves treatment risk and requires a great deal of control and carefully applied mechanics. However, in

some situation, function and esthetics demand reposition the tooth into the correct position without any harmful effect to the tooth bypass. The position of impacted canine was very helpful to us during surgical exposure and orthodontic correction of canine - lateral transposition. Orthodontic extrusion of dilacerated impacted central incisor showing successful and immediate esthetic improvement, by using of a single and simplified surgical procedure.

### **REFERENCES**

1. Mattos BSC, Carvalho JCM, Matusita M and Alves APP. Tooth transposition-a literature review and a clinical case. *Braz J Oral Sci.* 2006; 5(16): 953-957.
2. Fihora LC, Cardoso MA, Anc TL, and Bertozed FA. Maxillary canine –first premolar transposition. Restoring normal tooth order with segmented mechanics. *Angle Orthod.* 2007; 77(1):167-175.
3. Yilmaz HH, Türkkan H, and Ösayin M. prevalence of tooth transposition and associated dental anomalies in a Turkish population. *Dentomaxillofacial Radiology.* 2005; 34(1):32-35.
4. Shapira Y, Kuftinec MM. Maxillary canine-lateral incisor transposition. *Am J Orthod.* 1989; 95:5439-5444.
5. Shapira Y, Kuftinec MM. Maxillary tooth transposition: characteristic feature

- and accompanying dental anomalies. *Am J Orthod Dentofacial Orthop.* 2011; 119(2):127-134.
6. Sato K, Yokozeki M, Takagi T, Moriyama K. An orthodontic case of transposition of the upper right canine and first premolar. *Angle Orthod.* 2002;72(3):275-278.
  7. Göyenc Y, Karaman AL, Gökalp A. Unusual ectopic eruption of maxillary canine. *J Clin Orthod.* 1995; 29(9):580-582.
  8. Pi-Huei L, Eddie Hsiang-Hua L, Hsiang Y, Jenny Zwei-chieng C. Orthodontic treatment of a complete transposed impacted maxillary canine. *J of dental sciences.* 2013; 8 (4):341-452.
  9. Agnihotri A, Marwah N, Dutta S. Dilacerated unerupted central incisor: A case report. *J Indian Soc Pedod Prev Dent.* 2006; 24:152-154.
  10. Proffit WR, Field HW, Sarver DM, and Ackerman JL. Contemporary orthodontics. 5<sup>th</sup> edition. Pp 129-130.
  11. Stewart DJ. Dilacerated unerupted maxillary central incisors. *Br Dent J.* 1978; 145(8):229-233.
  12. Eddie HH, Lai FHC. Analysis of tooth transposition. *J Taiwan Assoc Orthod.* 2004; 16:38-43.
  13. Peck S, Peck L. Classification of maxillary tooth transpositions. *Am J Orthod Dentofacial Orthop.* 1995; 107: 505-517.
  14. Bocchieri A, Braga G. Correction of a bilateral maxillary canine-first premolar transposition in the late mixed dentition. *Am J Orthod Dentofacial Orthop.* 2002; 2(2): 120-128.
  15. Laino A, Cacciafesta V, Martina R. Treatment of tooth impaction and transposition with segmented arch technique. *J Clin Orthod.* 2001; 35(2): 79-86.
  16. Halazonetis DJ. Horizontally impacted maxillary premolar and bilateral canine transposition. *Am J Orthod Dentofacial Orthop.* 2009; 135(3): 380-389.
  17. Kolokithas G, Karakasis D. Orthodontic movement of dilacerated maxillary central incisor. *Am J Orthod.* 1979; 76(3):310-315.
  18. Wasserstein A, Tzur B, Brezniak N. Incomplete canine transposition and maxillary central incisor impaction. A case report. *Am J Orthod Dentofacial Orthop.* 1997; 111(6): 635-639.
  19. Tanaka E, Watanabe M, Nagaoka K, Yamaguchi K, Tanne K. Orthodontic traction of an impacted maxillary central incisor. *J Clin Orthod.* 2001; 35(6): 375-380.