

Histopathological Study of 5-Fluorouracil with and without Folic Acid administration on The Gastric Mucosa of Male Rabbits

Alhan Daham Hadi Al -Moula
BDS, MSc (Lec)

Department of Dental Basic Sciences
College of Dentistry, University of Mosul.

الخلاصة

الاهداف: يهدف البحث الى دراسة تأثير الفلورويوراسيل وكذلك الفلورويوراسيل مع حامض الفوليك على انسجة الطبقة المخاطية للمعدة عند الارانب. **المواد وطرائق العمل:** استخدمت في البحث الحالي 9 ذكور ارانب، أعمارهم تقريبا 3 أشهر، تم تقسيمهم الى ثلاث مجموعات رئيسية (3 أرانب لكل مجموعة). المجموعة الاولى: الضابطة، كمجموعة السيطرة اعطيت جرعة بمحلول ملحي متعادل. المجموعة الثانية: أعطيت 10 ملغم/كغم من الفلورويوراسيل بالحقن داخل الصفاق مرتين في الاسبوع ولمدة 8 اسابيع. المجموعة الثالثة: أعطيت 10 ملغم/كغم من الفلورويوراسيل بالحقن داخل الصفاق وفي نفس الوقت أعطيت 5 ملغم من حامض الفوليك فمويا بواسطة السرنجة الخاصة لها (cavage needle) مرتين في الاسبوع ولمدة 8 اسابيع. تم تشريح الحيوانات وأزاله الجسم (القاع) والبواب من المعدة وتجهيزها للدراسة النسيجية. **النتائج:** الفلورويوراسيل يسبب تشويه وفقدان للنظام النسيجي في الطبقة المخاطية للمعدة في الجسم والبواب مع وجود فقاعات في الساييتوبلازم للخلايا المبطنه للطهارة والنقر المعدي، وجود فقاعات في الساييتوبلازم في خلايا الغدد المعدي (الجداريات والرئيسية) وخلايا الغدد البوابية مع تهشم وتقطع في العضلات المخاطية مع احتقان الاوعية الدموية في الصفيحة الخاصة. وجود تشويه في الطبقة تحت المخاطية، والطبقة العضلية مع وجود فجوات واسعة بين الالياف العضلية الدائرية والالياف العضلية الطولية. بالمقارنة مع المجموعة الضابطة ماعدا المجموعة الثالثة التي أعطيت حامض الفوليك أظهرت قليلا من الاختلاف النسيجي المرضي في الطبقة المخاطية للمعدة في منطقة الجسم والبواب بالمقارنة مع المجموعة الضابطة. **الاستنتاجات:** الاستعمال الاسبوعي لعقار الفلورويوراسيل يسبب جروح في انسجة الطبقة المخاطية للمعدة. ولكن استعمال حامض الفوليك مع الفلورويوراسيل يوفر حماية من التأثير السام الداخلي لعقار الفلورويوراسيل.

ABSTRACT

Aims : To study the effects of 5-Fluorouracil (5-FU) on the gastric mucosa of rabbits and to evaluate the effect of folic acid (FA) on these effectiveness. **Materials and methods :** In the present study 9 adult male rabbits aged 3 months were used , and divided into 3 main groups. Group I: served as a control group and received normal saline only. Group II: given a twice dose of 10mg /kg per week 5-FU intraperitoneally for 8 weeks . Group III: given a twice dose of 10mg / kg per week 5-FU intraperitoneally with 5mg of folic acid orally by cavage needle for 8 weeks . The animals were sacrificed and the body and pyloric tissues of stomach were excised and processed for histological study. **Results :** 5-FU causes loss of tissues architecture in both body and pyloric regions of gastric mucosa with vacuolation in the cytoplasm of the cells lining epithelium and the cells lining the gastric pits, loss of gastric and pyloric glands architecture, vacuolation in the cytoplasm of the parietal and chief cells and the cells lining pyloric glands. Breached of muscularis mucosa, congestion of blood vessels in the lamina propria, vacuolation and dilated spaces in muscular layers. All these changes were significantly compare to control group except that for group III (5-FU plus FA) which showed few histopathological differences in whole thickness of gastric mucosa compare to control group. **Conclusions :** Weekly intraperitoneal administrations of 5-FU produce injury in the tissues of gastric mucosa. While combination 5-FU and folic acid (FA) regimen protect from enterotoxic action of 5-FU alone.

Key words : 5-fluorouracil ,folic acid ,stomach.

Al -Moula AD. Histopathological Study of 5-Fluorouracil with and without Folic Acid administration on The Gastric Mucosa of Male Rabbits *Al-Rafidain Dent J.* 2017; 17(1): 44-57.

Received: 15/9/2013

Sent to Referees: 29/10/2013

Accepted for Publication: 24/11/2013

INTRODUCTION

5-FU is a fluorinated pyrimidine antimetabolite which is structurally similar to uracil, one of the necessary building blocks in cellular division and growth,⁽¹⁾ 5-FU remains the most widely used agent in the treatment of colorectal cancer. It also has activity against a wide variety of solid tumors, including cancers of the breast, stomach and esophagus.⁽¹⁾ The use of 5-FU (chemotherapy) to treat stomach cancer before surgery to shrink the tumor or as adjuvant therapy after surgery to destroy cancer cells.⁽²⁾

In clinical practice, 5-FU is often combined with other cytotoxic agents such as methotrexate, cisplatin, vincristine, or drug which may enhance its effect on killing tumor cells such as leucovorin. Folinic acid also called leucovorin or the citrovorum factor is the reduced form of folic acid, is often used to potentialize the antineoplastic effect of 5-FU as a chemical modulator.⁽³⁾ Folinic acid is widely used to prevent the toxic effect and to strengthen the antineoplastic effect of 5-FU, in advanced gastric carcinoma patients receiving 5-FU and folinic acid.^(4,5) 5-FU should only be administered intravenously, the duration of therapy based on the type and course of the disease.⁽¹⁾ Another effect of fluorouracil and folinic acid in animals has been found colonic healing was impaired after intraperitoneal 5-FU administration, but when folinic acid was added no further deterioration occurred.⁽⁶⁾

The aim of this study to evaluate the effects of 5-FU on gastric mucosa of rabbits, also

to investigate whether the administration of folic acid provides any protection on 5-FU induced gastric mucosa damage.

MATERIALS AND METHODS

Nine adult male rabbits aged about 3 months weighing 0.950–1.640 kg were used and kept in a standardized animal house condition with room temperature $25 \pm 2^\circ\text{C}$ freely fed for 8 weeks. The animals were divided into 3 groups:

Group I: 3 rabbits were served as a control group and received normal saline orally by cavage needle

Group II: 3 rabbits given 10mg/kg of 5-fluorouracil in a twice weekly for 8 weeks intraperitoneally.

Group III: 3 rabbits given 10mg/kg of 5-fluorouracil intraperitoneally and 5 mg of folic acid orally by cavage needle at the same time twice weekly for 8 weeks.

After 8 weeks all animals were sacrificed by ether inhalation anesthesia. Abdominal dissection was done for all animals, the body and pyloric regions of stomach were excised, fixed in 10% formaline fixative for 24 hours, then dehydrated in ascending grades of alcohol, using 50% – 70% – 90% and 2 changes of absolute alcohol respectively with a period of one hour for each, procedure for preparing of paraffin section slides and staining with Hematoxyline and Eosin (H&E) was performed to obtain histological sections for light microscopic examination.⁽⁷⁾

RESULTS

Physical and clinical observations:

Side effects like mucositis which may lead to ulceration , diarrhea , toxicities such as

alopecia noticed in animals of group 11. Table(1).

Table (1): Body weight (gm) of rabbits before and after treatments

Groups	Animal No	Before treatment Body weight (gm)	After Treatments Body weight (gm)
Group I	1	950	1235
	2	1320	1405
	3	1400	1525
Group II	4	1595	1580
	5	1640	1535
	6	1470	1425
Group III	7	1465	1500
	8	1460	1525
	9	1270	1380

Showed that all animals in group II with a gradual and regular reduction in body weight, while the animals in group I and III showed increase in the body weight .

Control group

Group I :

The histological appearance of the normal gastric mucosa in body region shows the lining epithelium is tall columnar mucous cells with basally oval nuclei and clear staining cytoplasm with down growths the gastric pits.The mucous cells lining the pits are low columnar with basally oval nuclei . Below the gastric pits open the gastric glands . The upper end of the gastric glands lined by low columnar mucous neck cells with basally round nuclei which become continuous with the

mucous cells lining the pits as the glands empties into its base .The epithelium is supported by the lamina propria , which is consist of fine connective tissue with small blood and lymphatic vessels .The deep aspect of the lamina propria rest on the muscularis mucosa which consists of a thin band of smooth muscle fibers and send bundle of fibers toward the surface , interdigitating with the gastric glands.The submucosa is vascular lies between the mucosa and the main muscle layers . The distinction of the muscle layer into inner circular and outer longitudinal layers .

Between the two main smooth muscle layers are small blood and lymphatic vessels. Figure(1).

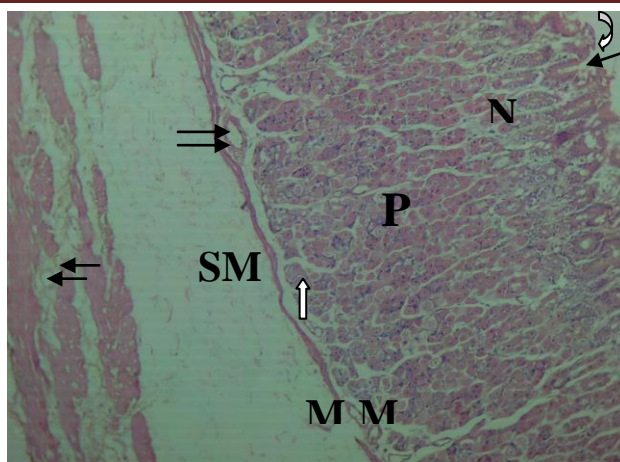


Figure (1): Light micrograph of rabbits gastric mucosa of group 1 in body region showing tall columnar mucous cells(curved arrow) of the lining epithelium .The gastric pit (arrow) , mucous neck cells (N) of the gastric glands open at the base of the pit .Numerous parietal cells(P) and chief cells(arrow) of the gastric glands .Small blood vessels(double arrow) in the lamina propria near the muscularis mucosa(MM), the submucosa (SM) between the mucosa and the muscular layers (M). H&E.[X-105].

The body mucosa is composed of tightly backed long straight tubular glands , that end blindly at the muscularis mucosa .The greater part of the gland is the body , the basal portion is the fundus , body and fundus are made up of large

pyramidal cells with central rounded nuclei (the parietal cells) taken acidophilic stain and chief cells which have large basal rounded nuclei taken basophilic stain .Figure(2).

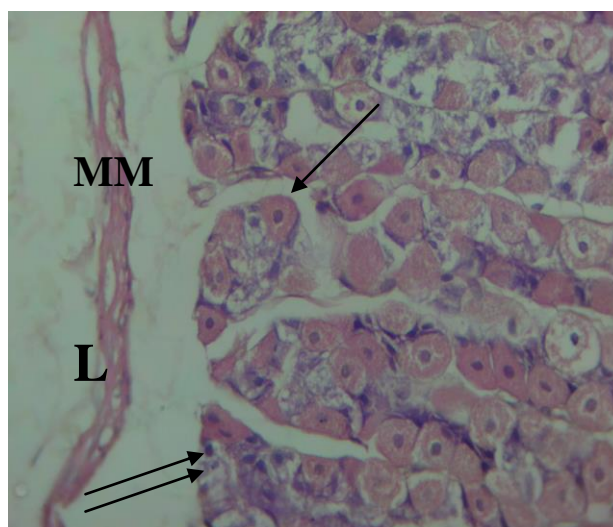


Figure (2) Light micrograph of rabbits gastric mucosa of group 1 in body region showing the parietal cells(arrow)acidophilic cytoplasm and the chief cells(double arrow)basophilic cytoplasm at the base of gastric glands.The deep aspect of the lamina propria(L) rest on the muscularis mucosa(MM).H&E. [X-420].

The histological appearance of the normal gastric mucosa in pyloric region shows the lining epithelium is tall columnar with basal oval nuclei and have bulky luminal cytoplasm , the gastric pits are deeper than those in the body, the mucous cells lining the pits are smaller and less regular in shape with basal oval nuclei .The lamina propria has branched pyloric glands , extensive vascular

supply . The muscularis mucosa in this region is thick ,irregular and smooth muscle fibers pass to meet the lamina propria .

The submucosa consists of blood vessels , lymphatic and nerves .Two layers of smooth muscle , an inner circular and outer longitudinal layer. Between them there are small blood and lymphatic vessels .Figure(3).

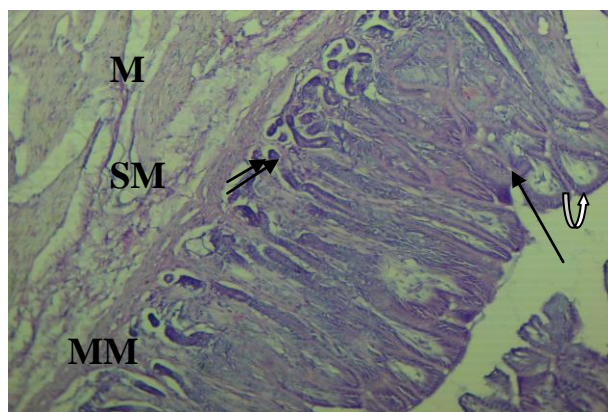


Figure (3) Light micrograph of rabbits gastric mucosa of group 1 in pyloric region showing tall columnar mucous cells(curved arrow) of the lining epithelium ,the gastric pit(arrow).The lamina propria have branched and tortuous pyloric glands(double arrow).The muscularis mucosa (MM) .The submucosa(SM) between the mucosa and the muscular layers(M).H&E. [X-105].

Deeply the pyloric mucosa composed of tortous single or branched pyloric glands extending down to the muscularis mucosa . The glands are

lined by tall columnar mucous cells with basal oval nuclei and granular cytoplasm .Figure (4).

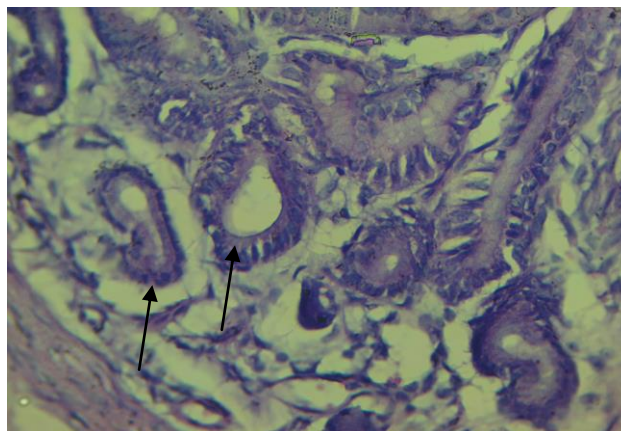


Figure (4): Light micrograph of rabbits gastric mucosa of group 1 in pyloric region showing tortuous single pyloric glands lined by tall columnar epithelium basally oval nuclei and granular cytoplasm (arrow). H&E. [X-420].

Treated Group

Group II: The histological appearance of the treated gastric mucosa in body region shows large vacuoles in the whole thickness of the mucosa, the

cells of epithelial lining irregular shape, atrophy and vacuolation in their cytoplasm, the gastric pits surrounded by empty spaces. Figure(5).

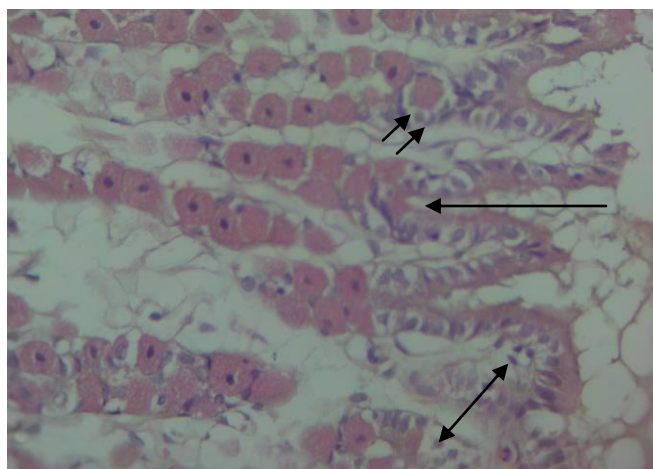


Figure (5): Light micrograph of rabbits gastric mucosa of group II in body region showing vacuoles in whole thickness of the mucosa (double head arrow). Vacuolation in the cytoplasm of the mucous neck cells (double arrow) of the gastric gland. Spaces in gastric pits (arrow). H&E. [X-420].

A congestion of the blood vessels in the lamina propria. The muscularis mucosa has been

breached. The muscle fibers show vacuoles and are separated by dilated spaces. Figure(6).

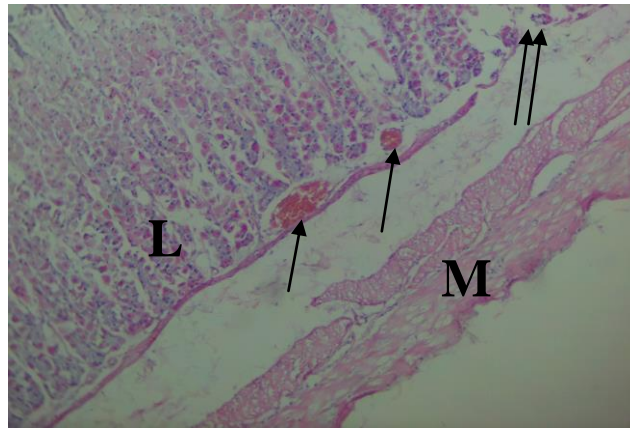


Figure (6): Light micrograph of rabbits gastric mucosa of group II in body region showing congestion of the blood vessels(arrow) in the lamina propria (L), breached of muscularis mucosa(double arrow), vacuoles and spaces in the muscular layers(M).H&E.[X-105].

The capillaries in the lamina propria are greatly distended with extensive hemorrhage deep to the muscularis mucosa .Loss of architecture of

gastric gland , the parietal and chief cells shows irregular shape , vacuolation in their cytoplasm surrounded by empty spaces . Figure(7).

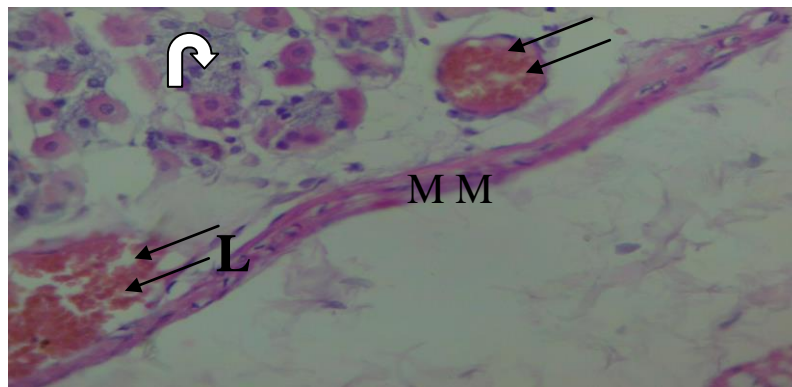


Figure (7): Light micrograph of rabbits gastric mucosa of group II in body region showing vacuolation in the cytoplasm of parietal cells (arrow) and chief cells (curved arrow).Congestion of blood vessels (double arrow) in the lamina propria (L) near the muscularis mucosa (MM).H&E.[X-420].

The histological appearance of the treated gastric mucosa in pyloric region shows atrophy in cells of epithelial lining , irregular shape of the cells lining the pits and pyloric glands ,

vacuolation in their cytoplasm , dilated space around the glands .The muscularis mucosa thinner than normal and breached . Dilated spaces in the muscle fibers and vacuolation .Figure(8).

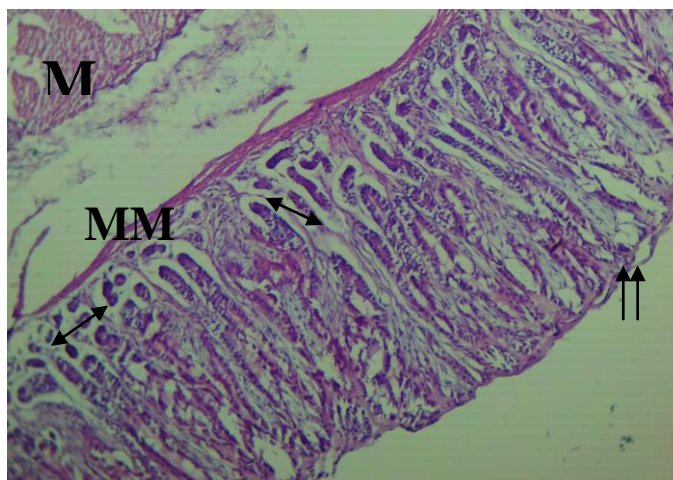


Figure (8): Light micrograph of rabbits gastric mucosa of group II in pyloric region showing atrophy in the lining epithelial cells(double arrow) .Dilated spaces between the pyloric gland(double head arrow). The muscularis mucosa(MM) thinner than normal & breached .Vacuoles & spaces in muscular layers(M).H&E.[X-105].

The lamina propria shows few distended vessels near the muscularis mucosa .Figure (9). capillaries and there is a little congestion of blood

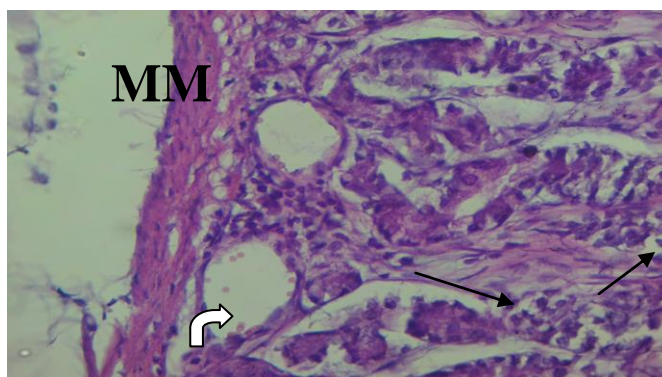


Figure (9): Light micrograph of rabbits gastric mucosa of group II in pyloric region showing vacuolation in the cytoplasm of cells lining the pyloric glands(arrow).Congestion of blood vessels (curved arrow) near the muscularis mucosa(MM).H&E.[X-420]

Group III

The histological appearance of the treated gastric mucosa in body region shows atrophy in the cells of epithelial lining , vacuoles in their

cytoplasm , regeneration in some of these cells, the epithelial cells lining the pits and the mucous neck cells are somewhat irregular in shape and vacuolation in their cytoplasm Figure (10).

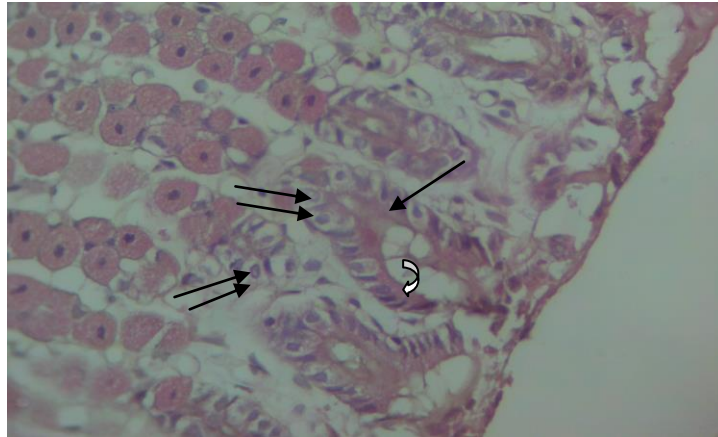


Figure (10): Light micrograph of rabbits gastric mucosa of group III in body region showing regeneration in some cells of the lining epithelium(curved arrow).Vacuolation in the cytoplasm of most epithelial cells (arrow) and mucous neck cells(double arrow) &the cells lining the pits(double arrow).H&E.[X-420].

No congestion of the blood vessels in the lamina propria near the muscularis mucosa , dilated spaces and vacuoles in the muscular layers .Figure (11). The capillaries in the lamina propria

are not distended and shows no congestion of blood vessels . Regeneration in most of the parietal and chief cells .Figure (12).

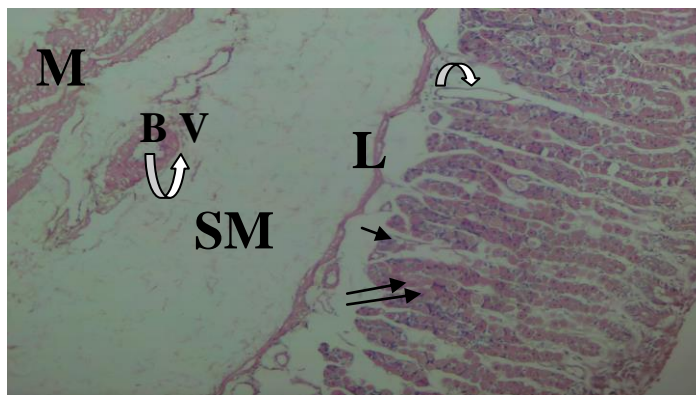


Figure (11): Light micrograph of rabbits gastric mucosa of group III in body region showing no congestion of blood vessels (curved arrow) in the lamina propria (L)and submucosa(SM).Regeneration in most of the parietal cells(double arrow) and chief cells(arrow).Vacuoles in muscular layers (M).H&E.[X-105].

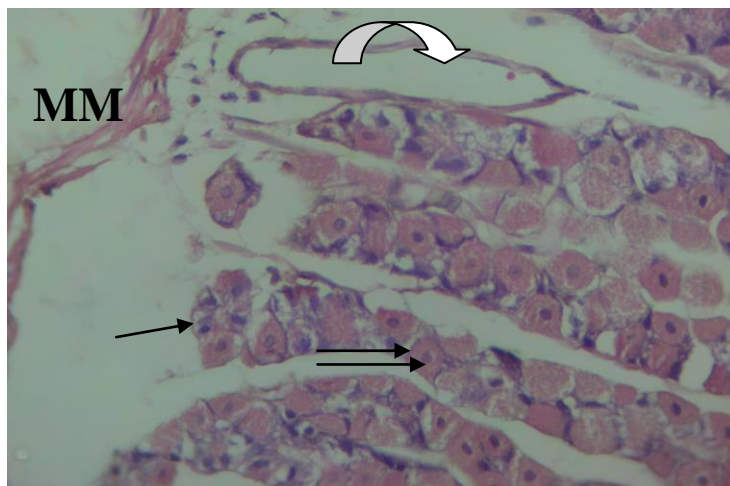


Figure (12): Light micrograph of rabbits gastric mucosa of group III in body region showing no congestion of blood vessels (curved arrow) in the lamina propria near the muscularis mucosa (MM). Regeneration in most parietal cells (double arrow) and chief cells (arrow). H&E. [X-420].

The histological appearance of the treated gastric mucosa in pyloric region shows regeneration in most of the cells epithelial lining, but there is spaces between the cells lining the pits

and the pyloric glands. The muscularis mucosa similar as in normal group. Dilated spaces and vacuoles in the muscular layers. Figure(13).

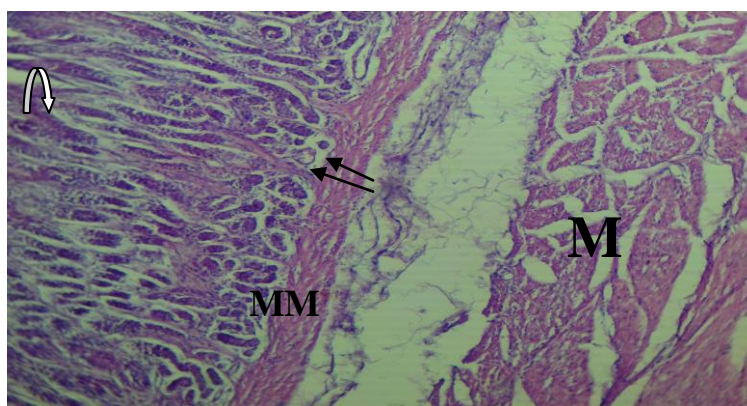


Figure (13): Light micrograph of rabbits gastric mucosa of group III in pyloric region showing regeneration in cells of lining epithelium (curved arrow). Vacuoles in the cytoplasm of the cells lining pyloric glands (arrow) near the muscularis mucosa (MM). Dilated spaces & vacuoles in muscular layers (M). H&E. [X-105].

No congestion of blood vessels in the lamina propria. Dilated spaces around the cells of the pyloric glands. Figure(14).

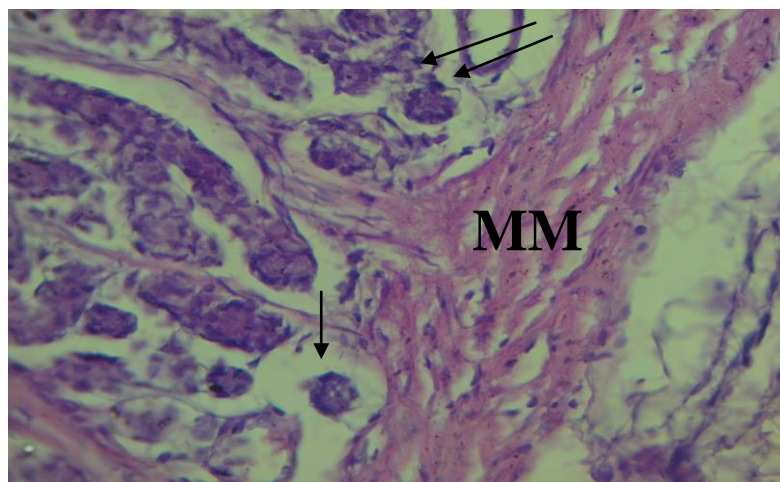


Figure (14) Light micrograph of rabbits gastric mucosa of group III in pyloric region showing vacuolation in cytoplasm of cells lining pyloric glands (double arrow).Dilated spaces around the glands (arrow). Vacuoles in muscularis mucosa(MM).H&E.[X-420].

DISCUSSION

The stomach is a muscular organ of the gastrointestinal tract that hold food and begins the digestive process by secreting gastric juice .In order to determine cancer is present in the stomach , histopathological analysis useful as a diagnostic tool by take samples of the suspected mass to confirm cancer .⁽⁸⁾ More than half of all people diagnosed with cancer receive chemotherapy regimen , including drugs to treat cancer as well as drugs to help support the completion of the cancer.⁽⁹⁾

The present study in animal revealing adverse side effects of 5-FU alone and 5-FU with FA .Male rabbits treated with 5-FU showed decrease in body weight . Dissection of these animals indicated that the loss of the body weight were due to loss of skeletal muscles and adipose tissue. ⁽¹⁰⁾ Moreover,the reduction in body weight of the animals in this study correlate with the

decreased food intake observed during the experimental period. Stomatitis,alopecia and diarrhea were observed in the study. It may be due to lack of folic acid supplementation. This is in agreement of other studies reported that approximately 15% of patients treated with chemotherapy develop several oral or gastrointestinal complications during the treatment. ⁽¹¹⁾ Patients are at significantly increased risk of developing severe toxicity like mucositis and diarrhea when treated with 5-FU .⁽¹²⁻¹⁴⁾ The epithelial atrophy, loss of tissues architecture, vacuolation in the cytoplasm of the cells epithelial lining and the cells lining gastric pits, loss of architecture in both gastric and pyloric glands ,vacuolation in the cytoplasm of both parietal and chief cells and the cells lining the pyloric glands and dilated spaces. These marked changes were observed in rabbits of group II suggests cell death can result from pathologically occurring apoptosis

.^(15, 16) 5-FU inducing cell cycle arrest and apoptosis by inhibiting the cells ability to synthesize DNA.⁽¹⁾ While toxicities such as loss of weight, alopecia, diarrhea, and loss of tissues architecture were not observed in rabbits of group III receive 5-FU with FA, there was a regeneration in some of the cells epithelial lining and most of the cells lining the gastric and pyloric glands. This is due to biochemical rationale for the synergism produced by the combination of 5-FU and leucovorin.

Leucovorin is metabolized to reduced folate co-factor that is necessary for maximal inhibition of thymidylate synthetase by FD-UMP, the active metabolite of 5-FU.⁽¹⁾ Other studies demonstrate that combination 5-FU and folinic acid regimen shows good efficacy and an acceptable safety profile in metastatic gastric cancer patients, and may prove to be suitable alternative regimen in this indication.^(5,17) The congestion of the blood vessels in the lamina propria of gastric mucosa in both body and pyloric regions in rabbits of group II receiving 5-FU may be due to acute inflammation associated with injuries, after transient (seconds) vasoconstriction, arteriolar vasodilation occurs, resulting in locally increased blood flow and engorgement of the down-stream capillary beds. Subsequently, the microvasculature becomes more permeable, resulting in the movement of protein-rich fluid into the extra vascular tissues. This causes the red blood cells to become effectively more concentrated, thereby increasing blood viscosity and slowing the circulation. These changes are

reflected microscopically by numerous dilated small vessels packed with erythrocytes.⁽¹⁸⁾ Vacuolation and dilated spaces in muscular layers of gastric mucosa in both body and pyloric regions, these side effects of 5-FU are probably due to inhibition of DNA synthesis.⁽¹⁾ Therefore 5-FU affect not only tumor cells but also rapidly dividing cells such as gastrointestinal mucosa, where it inhibits epithelial proliferation and induced apoptosis.^(5,19) Folinic acid which is metabolized to a reduced folate, is able to modulate the antineoplastic effect of 5-FU.⁽¹⁾ The congestion of the blood vessels in the lamina propria were not observed in group III after receiving FA, vacuolation and dilated spaces in the muscular layers in both gastric and pyloric regions were noticed. Similarly, studies of the effect of folinic acid in 5-FU induced killing of human tumor cell lines in vitro found that the cell of origin, the dose, and the duration of exposure to folinic acid all influenced cytotoxicity.⁽²⁰⁾

CONCLUSIONS

This study identified pathological features of the tissues architecture, which could be used as the basis for determining the appropriate dose of these drugs to reduce their cytotoxic effects. Low concentration of oral administration of folic acid cannot protect the luminal gastric mucosa from being injured by the enterotoxic action of 5-fluorouracil. Study suggests a new regimens (intraperitoneal 5-FU plus daily high dose of oral administration of folic acid) are needed to further increase survival in patients with gastrointestinal

cancers and to reduce the acute toxic effects of this drug.

REFERENCES

- 1- Katzung B ,Masters S , and Trevora A. Cancer chemotherapy. In : Basic and clinical pharmacology. LANGE .12th.ed. 2012 ; p.949-960.
- 2- Scartozzi M,Galizia E,VerdecchiaL,and cascino S. Chemotherapy for advanced gastric cancer . standered of care .*Expert opinion on pharmacotherapy* 8.2007;6: 797-808.
- 3- Feza Y. Karakayali, Sancar B. and Selcuk H. Does folinic acid have acholeretic effect on humans.*The Turkish Journal of Gastroenterology*.2003;14 (2):102-105.
- 4- Loss,Wu Cw,and Chikh kl. Concomittant chemoradiation treatment in the managment of patients with extraheptic biliary tract recurrence of gastric carcinoma. *Cancer*. 2000;89:29-34.
- 5- Louvet C, Andre T, Jacob J .H ,and Gramont A. Phas II study of Oxaliplatin,Fluorouracil,and folinic acid in locally Advanced or Metastatic Gastric Cancer patients. *American Journal of Clinical Oncology* .2002;20(23):p. 4543-4548.
- 6- Graf W, Weiber S, Glimelius B, and Zederfeld T. Influence of 5-fluorouracil and folinic acid on colonic healing: an experimental study in the rat.*Br J Surg*. 1992;79(8):825-8.
- 7- Humanson G. Animal tissue technique. San Francisco W.H. Freeman and company .3rd ed.1972;p.125-136.
- 8- Withrow S.J, Macewen EG, ed. Small Animal Clinical Oncology. W.B. Sanders Company .3rd ed.2001:10.
- 9- Bonadonna G, Valagussa P, and Brambilla C. Adjuvant cyclophosphamide, methotrexate, and fluorouracil in node-positive breast cancer: the results of 20 years of follow-up.N *Engl J Med*. 1995;332:901-906.
- 10- Devlin TM . Text book of biochemistry : with clinical correlation . 4th ed. New York : John Wiley and sons Inc. 1997:553.
- 11-Jones JA , Arritscher EB , Cooksley CD and Elting LS. Epidemiology of treatment-associated mucosal injury after treatment with newer regimens for lymphoma, breast, lung, or colorectal cancer. *Support care cancer* . 2006;14:505-515.
- 12-Lee A, Ezzeldin H, and Fourie J. Dihydropyrimidine dehydrogenase defeiciency: impact of pharmacogenetics on 5-fluorouracil therapy. *Clin Adv Hematol Oncol*. 2004;2: 527-32.
- 13-Schwab M, Zanger UM, and Marx C. Role of genetic and nongenetic factors for fluorouracil treatment-related sever toxicity :a prospective clinical trial by the German 5-FU toxicity study group. *J Clin Oncol*. 2008;26:2131-8.
- 14-Amstutz U , Froehelich TK , and Largiader CR. Dihydropyrimidine dehydrogenaseas a major predictor of sever 5-fluorouracil toxicity . *Pharmacogenomics*.2011;12: 1321-36.

- 15–Farber E. Programed cell death : Necrosis versus apoptosis. *Mod pathol* .1994;7:605–609.
- 16–Yagiela A, Dowd F, Neidle E. Antineoplastic drugs. In: pharmacology and therapeutics for dentistry. Elsevier Mosby.5th ed.2004; p.697–799.
- 17–Mauer AM, Kraut EH, and Rudin CM .Phase II study of oxaliplatin , fluorouracil, and leucovorin in metastatic carcinoma of the esophagus/gastric cardia.Proc. *Am Soc Clin Oncol*. 2001;20:163.
- 18–Kumar V, Cotran R, and Robbins S. Acute and chronic inflammation. In: Basic pathology.Saunders An Imprint of Elsevier. 7th ed. 2003;p.35.
- 19–Muller–Koch Y, Vogelsang H, and Kopp R. HNPCC clinical and molecular evidence for a new entity of hereditary colorectal cancer .*Gut*. 2005;24:1676–8.
- 20–Blamgren H, Edler D , Hallstrom M, and Ragnhammar P. Dual effects of folinic acid in 5–fluorouracil induced killing of human tumor cell lines in vitro .*Anticancer Res*. 1996;16: 2713.