

Changes in blood parameters and kidney histology due to cadmium and selenium exposure of Female rat[♦]

Ahmed Baker Ali

Biology Department / Education college / Mosul University

الخلاصة

يهدف البحث الحالي إلى دراسة تأثير الكاديوم (Cd) والسيلينيوم (Se) على معايير الدم والتركيب النسيجي للكلية في إناث الجرذان . قسمت الجرذان إلى مجموعة سيطرة ومجموعتين تجريبيتين معاملة بـ (Cd و Se) عن طريق التجريع الفموي . في نهاية الفترة التجريبية (28 يوما) شحنت الجرذان وجمعت عينات الدم من القوس الوريدي الظهري وتم دراسة نسبة حجم تراص كريات الدم الحمر (PCV) ،خضاب الدم (Hb) ، العدد الكلي لكريات الدم الحمر (RBC) ، العدد الكلي لخلايا الدم البيض (WBC) . كما شحنت الكلية لغرض الفحص النسيجي . أظهرت الدراسة أن هناك تغيرا في قيم الـ RBC ، WBC ، PCV و Hb في الجرذان المعاملة بالكاديوم (Cd) وكان التغير معنوياً ($P < 0.05$) . كذلك أظهرت نتائج الدراسة عدم وجود تغيرات في معايير الدم للجرذان المعاملة بـ (Cd+Se) مقارنة بحيوانات السيطرة . لوحظ العديد من التغيرات المرضية النسيجية في الكلية والتي تضمنت انكماش بعض الكبيبات ، تنكس في خلايا النبيبات البولية ، تحلل انوية بعضها وأخيرا موت بعضها في الحيوانات المعاملة بالكاديوم بينما أظهرت الحيوانات المعاملة بـ Cd+SE إعادة إصلاح واضحة .

Abstract

The purpose of the study was to investigate the effect of Cadmium and selenium on blood parameters and the subsequent effect in the tissue of female rat kidney . Female rats were divided into a control group and tow experimental groups treated with Cadmium, and Cadmium +Selenium. A control and tested animals were fed with the same standard chow , but Cadmium chloride, and Cadmium + Selenium mixture were orally gavaged daily for 28 days .At the end of the experimental period, blood samples were analyzed ,and packed cell volume (PCV %) , hemoglobin (Hb) , number of total erythrocytes count and total leucocytes count were determined . Blood analyses carried out in the present study showed that cadmium treatment causes different alterations in blood parameters as indicated by significant decrease in erythrocytes

[♦]Presented at the first conference on Biology , University of Mosul ,college of Education , 4 - 5 September 2007

count , hemoglobin value and packed cell volume percentage as compared to control and Cd+selenium treated group . A number of histopathological change were observed in the kidney , including glomerular shrinkage, karyolysis , degenerative cell and cell necrosis at cadmium treatment and pronounced recovery after selenium co-supplemented showing a considerable antagonistic effects of Selenium + cadmium treatment .

It can be concluded that the Cd exposure impair certain hematological mechanism and increase kidney tissue damage .Selenium showed beneficial effects to some extend. This study provide data on toxic effect in female rats after dietary sub lethal supplementation to heavy metals.

Keywords : Cadmium , blood parameter , histopathology.

Introduction

Variety of toxicants were found to induce hematological alterations after prolonged administration [1]. Cadmium is a heavy metal abundant in the environment that induce abroad range of physiological dysfuctions ,recently , increasing attention been drawn to the effects of metals and metal compounds on human and animal health .Metals accumulates in the various organs and tissues and bound to erythrocytes [2] and eventually it is exerted through glomerular filtration in the kidney. Cadmium as other metals and toxicant materials may have toxic effects on blood parameters and kidneys ,depending either on dose taken up or chronic toxic effects can be caused [3] . The most obvious toxic effects of metals appears in the hepatopoiesis process and it has been proposed that metals induces anemia in addition to the knowledge shortened life span of erythrocytes and inhibition of hemoglobin synthesis [4].

The histological examination also revealed important differences between cadmium treated group and Cd+Se group. There was different grade of damage in the morphology of kidney tissue including glomeurlus shrinkage , uniferous degeneration. Free radicals are in living body highly reactive and the abnormal production of free radicals attack cell content which lead to considerable damage to cell structure [5] .Histological studies showed that antidote preserved tissue organ architecture changes induced by various toxic chemical due to their free radical scavenging proportion and oxidative stress inhibiting ability [6 and 7]. However paucity data on the antagonistic Co-treated rats to both toxicant and antidote available .The antagonistic effect of selection introduced was undertaken into consideration in this study as antioxidant diet.

The aim of the present work to report detailed toxic effect on rats blood parameter and kidney architecture of the sublethal chronic exposure to cadmium and the possibility of supplementing selenium as potent antidote for curative purpose.

Materials and Methods

Total of 21 adult female albino rats weighing 240 – 260 g were used in this study . CdCl_2 was freshly dissolved in deionized water and the desired concentrations diluted from the stock solution (1ppm.). Before supplementation, female were rats divided into a control and tow experimental groups (groups of rats $n= 7$) . Animals were fed normal chow diet, but Cd and Cd +Se were administrated by oral gavage in the test animals . The first group was served as vehicle (untreated control) , the second group supplemented (0.7.mg / kg b.w.) CdCl_2 , and the third group supplemented mixture of 1:1 (0.8.mg / kg b.w.) Selenium Chloride and (0.7.mg / kg b.w.) CdCl_2 .

At the end of the experimental period (28 days) animals were anesthetic by ether and blood was drawn via the dorsal vena cava and placed into tubes containing EDTA in the spiramix and then the hematological blood was measured using automatic hematological analyzer(CoulterACT differential analyzer, Documentation, Bakman Coulter, Inc. Industrial Estate , Germany) . The hematocrit (P.C.V.) , Red blood cells count , total White blood cells count and differential percentage of lymphocytes , monocytes , granulocytes were counted .

For light microscopic preparation, rats were killed by anesthetic overdose using ether. kidney was dissected out and small portion of the kidney fixed in Bouin's solution for 16h and subsequently placed in 70% ethanol . dehydrated in ethanol series, cleared with xylene, infiltrated and embedded in paraffin wax . Thin section (5 μ) were cut and stained with hematoxylin - eosin for histological examination.

The data were analyzed using one way - ANOVA with a Duncan post test (SPSS , V.11.5 for widows) for significant differences .

Result

Results of the present study under taken the chronic effect of cadmium sublethal dose on blood parameters and kidney architecture .

Table (1) shows the various hematological parameters including the packed cell volume , red blood cells count total white blood cells count and differential count and percentage of(lymphocytes , monocytes , granulocytes) , platelets , mean cell volume, mean corpuscular hemoglobin, mean corpuscular hemoglobin concentration in the three groups of rats . The erythrocyte count , leukocyte count , hemoglobin and packed cell volume percentage of Cd-treated group were found to be

significantly lower than both control and Cd+Se treated group, other blood parameter although showed different positive or negative altered values, but statically these differences were not significant.

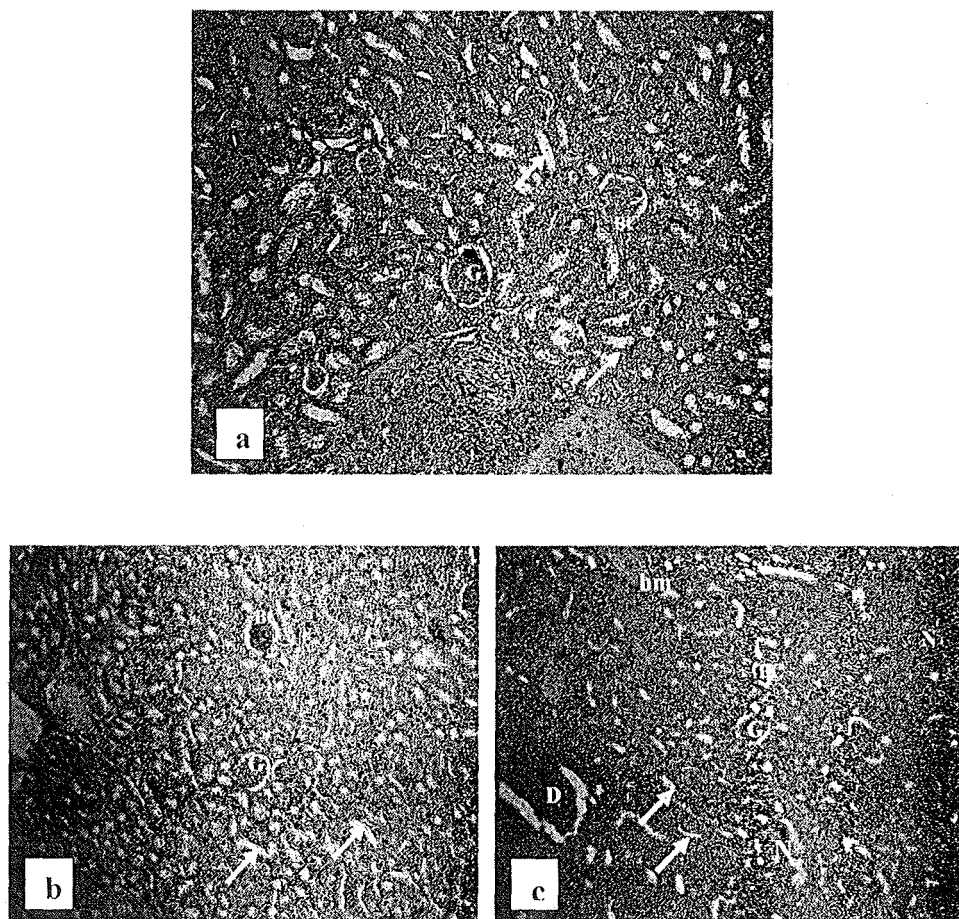
Table .2 . Hematological analyses of female rats blood after different treatments

Hematological parameters	Non - treated	Cd	Cd + Se
WBC _s x 10 ³ mm ³	16.66 ± 0.698	7.08 ± 0.78**	18.18 ± 3.123
RBC _s x 10 ⁶ /mm ³	7.564 ± 0.301	6.658 ± 1.25*	7.168 ± 0.399
Hb gm/ dl	14.88 ± 0.44	12.22 ± 1.179*	14.66 ± 0.355
PCV %	41.68 ± 5.35	36.26 ± 6.602*	43.32 ± 1.343
% Granulocyte	25.62 ± 2.123	13.66 ± 2.682*	14.36 ± 3.454
Lym x 10 ³ /mm ³	12.48 ± 0.249	5.32 ± 0.973**	12.00 ± 2.745
Mon x 10 ³ / mm ³	1.44 ± 0.397	1.16 ± 0.054*	1.66 ± 0.4505
Gran 10 ³ / mm ³	2.74 ± 0.0391	0.84 ± 0.364***	4.82 ± 0.396**
% Lymphocyte	67.34 ± 2.355	71.78 ± 6.448**	63.56 ± 3.656
% Monocyte	7.04 ± 0.835	16.14 ± 1.226	8.88 ± 2.193
MCV (nm ³)	60.22 ± .3.552	52.94 ± 1.457	54.48 ± 1.896*
MCH (Pg)	20.34 ± 0.1381	18.4 ± 0.57	18.86 ± 0.296
MCHC (g / dl)	34.68 ± 0.2.111	34.6 ± 0.114	34.7 ± 0.809
Platel. x 10 ³ /mm ³	836.4 ± 55.4	365.8 ± 30.08	867.6 ± 55.716

*, **, *** there are significant differences at (p<0.05)

Fig(1). Showed the control rat kidney feature (a) and the various histological alterations in kidney architecture due to different treatment .The peripheral cells demonstrated karyolysis whereas the number of necrotic, hemosidren pigments and degenerative cells increased .The renal tubules were found to lose their regular shape and the intratubular cavity decreased significantly (b). While with cadmium+selenium combination treatment a remarkable recovery observed , the karyolysis,

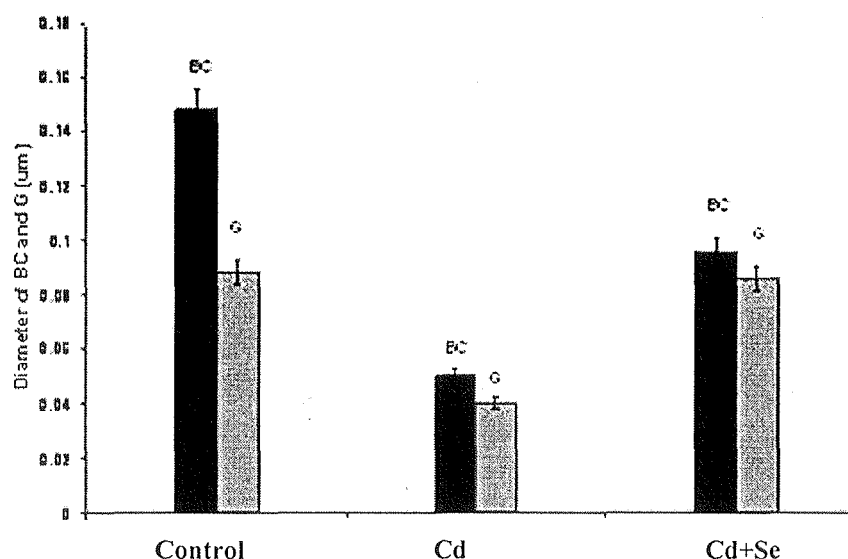
necrosis and degeneration were scanty and the intratubular cavity were almost regained their normal shape and the intertubular perform there normal size(c)



Fig(1). (a)Transverse section of kidney of non treated rats (control)
(b)Transverse section of kidney of rats treated with Cd
(c)Transverse section of kidney of rats treated with Cd +Se
H &E stained 450x

(BC- Bowman's capsule , G- glomerulus, arrows intratubular cavity ,
N- necrosis ,hm- hemosidren pigments and D – degeneration)

Also the result of the present study showed that the glomeruli appeared to be shrink with Cd –treatment and an increase was appeared in the Bowman's space and decrease in both Bowman's capsule and glomerular size , while with Cd +Se treatment the recovery was obvious in which the Bowman's capsule in glomerulus almost of normal diameter fig(2).



Fig(2) . Bowman's capsule and glomerulus diameter(μm) rat kidney subjected to different treatments(BC: Bowman's capsule – G : glomerulus)

Discussion

The major challenge in experimental toxicological studies is to develop proper chronic biomarkers the best possible environmental diagnostics[8] The present study investigated the effects of long-term treatment with sublethal doses of cadmium on the blood parameters and histological architecture of the kidney in the rats . Our results in the present study under taken the chronic effect of cadmium sublethal dose on blood parameters and kidney architecture The results showed that blood parameters significantly changed due to cadmium exposure and kidney were markedly injured. This finding are supported by previous case reports that described significant differences in blood parameters between non-treated and treated group as well as revealed that chronic treatment induces marked cytoplasmic vacuolation of kidney tubules[9]

Result in table(1)-showed –the number of erythrocytes , the packed cell volume and hemoglobin values in the experimental animals given Cd. by cavage contain(0.7 mg/kg b.w.) as the cadmium chloride was found to be lower than in the control and rat group given (0.7 mg/kg b.w. Cd mixed with 0.8 mg/kg b.w. Se as selenium chloride). It is known that toxicant impair the heme synthesis and this probably related to the inhibition of the hemoglobin synthesis and to various alteration of erythrocyte membrane properties , leading to an increased fragility of RBC and eventually to RBC destruction [10] The effect of metal on red blood cells membrane in particular have been intensely analyzed because RBC are more vulnerable to oxidative damage than many other cells [11]. A part from directed inducing the generation of reactive oxygen

species (ROS), an element can indirectly induce oxidative stress by increase the vulnerability of membrane to the attack of ROS. In conclusion , it can be stated that cadmium increase the production of ROS and resulting destruction of the RBC membrane and its function [2]. Authors reported the accumulation metals in various organs and tissues and excreted through glomular filtration , but they did not explain the consequences of pathway impact[12] .In the present investigation 0.7 mg /kg b.w. dose of cadmium chloride (Cd Cl₂) resulted in discrete histopathology in the kidney it was evident that was by the end of the experimental period there was a shrinkage in Bowman's capsule space followed by enlargemat of glomerulus(fig 1b) and a normalization of Bowman's space during the phase of Cd+Se treatment (fig1c).Increase in Bowman's space suggests an increase in the filtration rate ,this may be a mechanism to overcome the toxic effect (11&12).With Cd+Se treatment a marked recovery observed , the tubules regained their regular shape and the intertubular space perform a normal size (fig2c arrows).

References

- [1]Kara, M.N; Pauwels, A; Pines, E; Biour, M and Levy, W.E. Lancet .340:674-676.(1992).
- [2]Toplan , S ; Özcelik , D ; Gulyasar , T and Akyolcu , M . C . 2004 . changes in hemorhological parameters due to lead exposure in female rats . J .Trac. Med. Biolo. 18 : 179 – 182 .
- [3]Skerfving , S;erhardsson , LandSclutz, A.J.Trace Elem.Exp.Med.11:289-301.
- [4]Osterod , W; Barns, U and Geiser, K. Occup.Environ.Med.56:106-109.(1999) [5]Mastsumoto K, Okajo A , Kobayashi T , Mitchell JB , Krishna MC and Endo K. R. J. Biochem. Biophys. Methos . 63 : 79 – 90 .(.2005 .)
- [6]El-Bahy GM and Ismail ZMK.Isotope and RAD .Res. 29(1,2) : 39 – 52(1997)
- [7]Reiter RJ , Tan DX , Qi w , Manchester LC , Karbowink M , and Calri JR . Biol Signal ,Recept. 9 : 160 -171 .(2000) .
- [8]Rabitto J.S , Costa , A , Assis , S, Pelletie , E, Akaishi , M.F ; Anjos , A , Randi, M.A.F and Ribeiro, O. Ecotoxicology and environmental safety, 60 147-156(2005).
- [9]Khleifat, K; Shakmanbeh, J and Tarawneh, K. Turk.J.Biol. 26: 65-71.(2002)
- [10]Zimmermann, L; Payes, N; Anteb, H, Hatfi, A; Bounder, C and Alcindor, L. C.Biol. Tace.Elem.Res..38 : 311 – 318 .(1991) .
- [11]DeSliva , P. E. Br .J. Ind. Med. 38: 209 - 217. (1981).
- [12]Bahatacharya, T; Ray, A. K and Bahatacharya, S. Zool.Jb. Anat. 115:263-272.(1987)